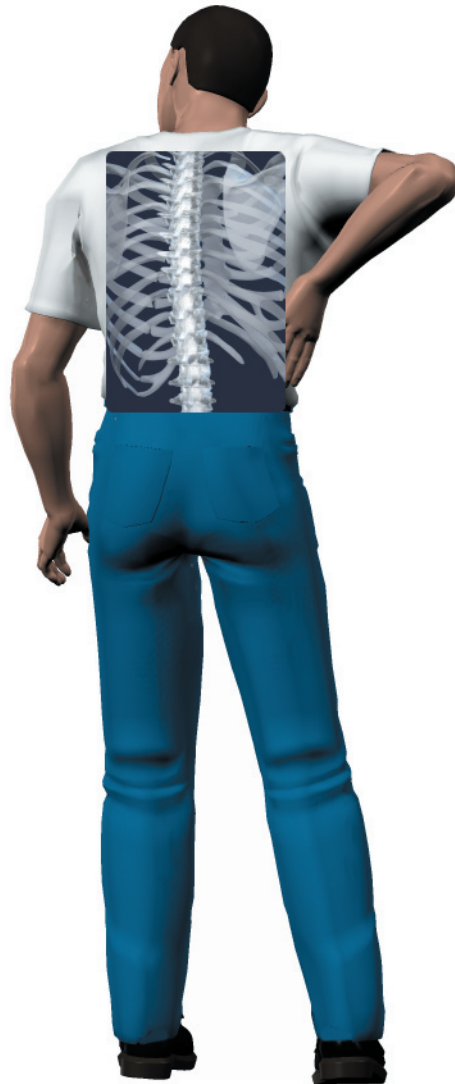

## *A Patient's Guide to* **Thoracic Spine Anatomy**



©MMG 2003



**STERLING RIDGE  
ORTHOPAEDICS**  
& SPORTS MEDICINE

**Sterling Ridge Orthopaedics & Sports Medicine**  
6767 Lake Woodlands Drive, Suite F, The Woodlands, TX  
77382  
20639 Kuykendahl Road, Suite 200, Spring, TX 77379  
The Woodlands & Spring, TX .



**STERLING RIDGE  
ORTHOPAEDICS**  
& SPORTS MEDICINE

## **Sterling Ridge Orthopaedics & Sports Medicine**



If you are experiencing pain, feel symptoms of an orthopedic condition or you've just been diagnosed, we encourage you to use our online patient education library to learn about the condition and what can be done. This can help you prepare for an appointment and serve as a review of the information your physician shares. Feel free to read the information online or download a PDF to print or share.

At Sterling Ridge Orthopaedics & Sports Medicine we provide each patient with the highest level of care by board certified physicians. Please schedule an appointment with one of our specialists if you have any questions or concerns about symptoms you may be experiencing.

Two convenient locations:

### **THE WOODLANDS**

281-364-1122

6767 Lake Woodlands Drive, Suite F  
The Woodlands, TX 77382

### **SPRING**

832-698-0111

20639 Kuykendahl Road, Suite 200  
Spring, TX 77379

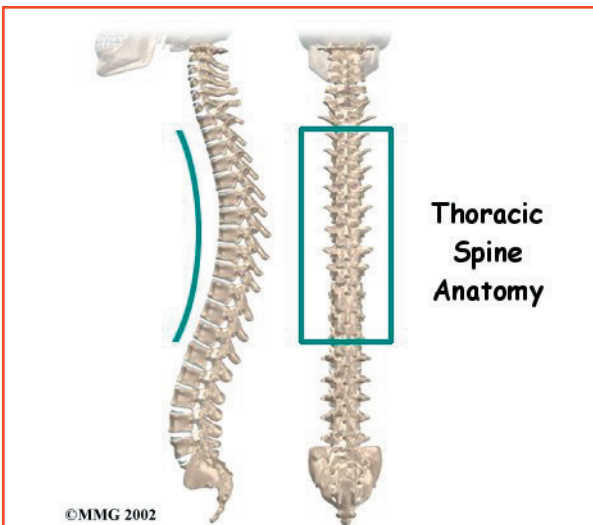


**STERLING RIDGE  
ORTHOPAEDICS**  
& SPORTS MEDICINE

Sterling Ridge Orthopaedics & Sports Medicine  
6767 Lake Woodlands Drive, Suite F, The Woodlands, TX  
77382

20639 Kuykendahl Road, Suite 200, Spring, TX 77379  
The Woodlands & Spring, TX .

Phone: 281-364-1122 832-698-0111  
stacy@srosm.com



## Introduction

The section of the spine found in the upper back is called the *thoracic spine*. It goes from the base of the neck to the bottom of the rib cage. Knowing the main parts of the thoracic spine and how these parts work is important as you learn to care for your back problem.

Two common anatomic terms are useful as they relate to the thoracic spine. The term *anterior* refers to the front of the spine. The term *posterior* refers to the back of the spine. The front of the thoracic spine is therefore called the *anterior thoracic area*. The back of the thoracic spine is called the *posterior thoracic area*.

**This guide gives a general overview of the anatomy of the thoracic spine. It should help you understand**

- what parts make up the thoracic spine
- how these parts work

## Important Structures

The important parts of the thoracic spine include

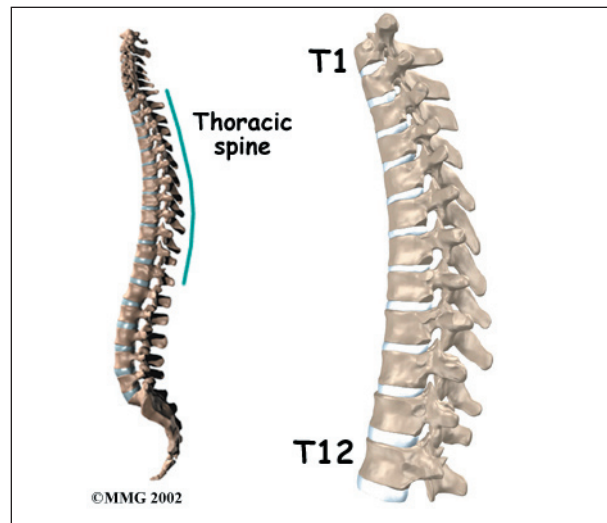
- bones and joints
- nerves
- connective tissues

- muscles
- spinal segment

This section highlights important structures in each category.

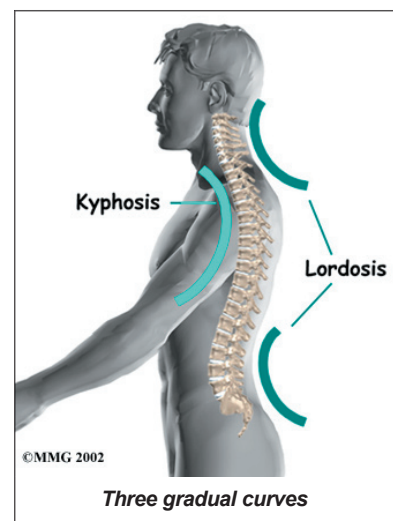
### Bones and Joints

The human spine is made up of 24 spinal bones, called *vertebrae*. Vertebrae are stacked on top of one another to create the *spinal column*. The spinal column is the body's main upright support.

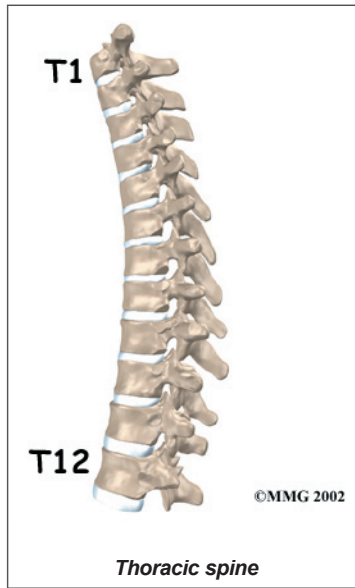

From the side, the spine forms three curves. The neck, called the *cervical spine*, curves slightly inward. The thoracic spine curves outward. The low back, also called the *lumbar spine*, curves slightly inward. An inward curve in the spine is called *lordosis*.

An outward curve, as in the thoracic spine, is called *kyphosis*. The kyphosis is shaped like a *C* with the opening in front.

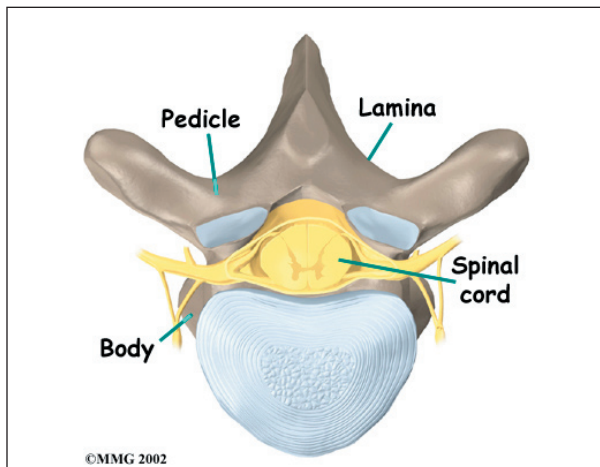


The middle 12 vertebrae make up the **thoracic spine**. Doctors often refer to these vertebrae as T1 to T12. The large bump on the back of the lower part of the neck is the seventh cervical vertebra, called C7. It connects on top of T1. The lowest vertebra of the thoracic spine, T12, connects below the bottom of the rib cage to the first vertebra of the lumbar spine, called L1.



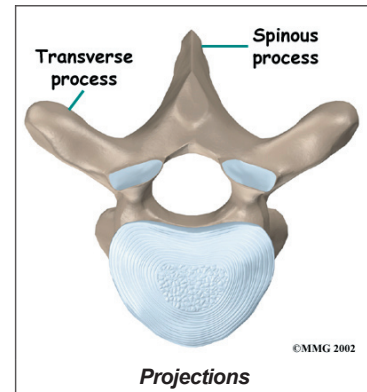
Each vertebra is made of the same parts. The main section of each thoracic vertebra from T1 to T12 is formed by a round block of bone, called the *vertebral body*. Each vertebra increases slightly in size from the neck down. The increased size helps balance and support the larger muscles that connect to the lower parts of the spine.

A bony ring attaches to the back of each vertebral body. This protective ring of bone surrounds the spinal cord, forming the spinal canal. Two *pedicle bones* connect directly to the back of the vertebral body. Two lamina



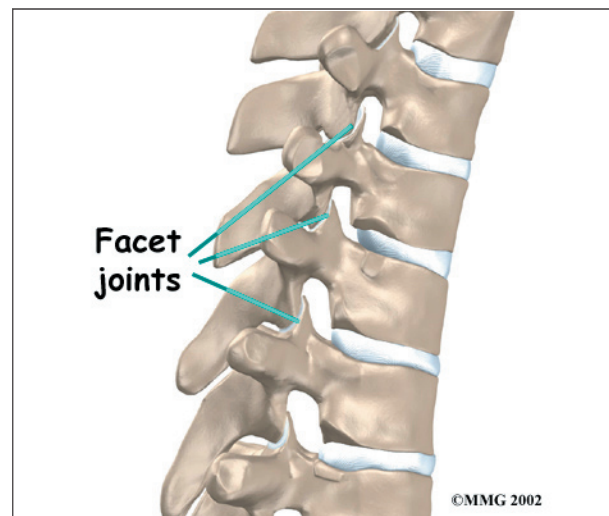
bones join the pedicles to complete the ring. The *lamina bones* form the outer rim of the bony ring. When the vertebrae are stacked on top of each other, the bony rings form a hollow tube that surrounds the spinal cord and nerves. The laminae provide a protective roof over these nerve tissues.

A bony knob projects out at the point where the two lamina bones join together at the back of the spine. You can feel these **projections**, called *spinous processes*,



as you rub your fingers up and down the middle of your back. Bony knobs also point out from the side of the bony ring, one on the left and one on the right. These projections are called *transverse processes*.

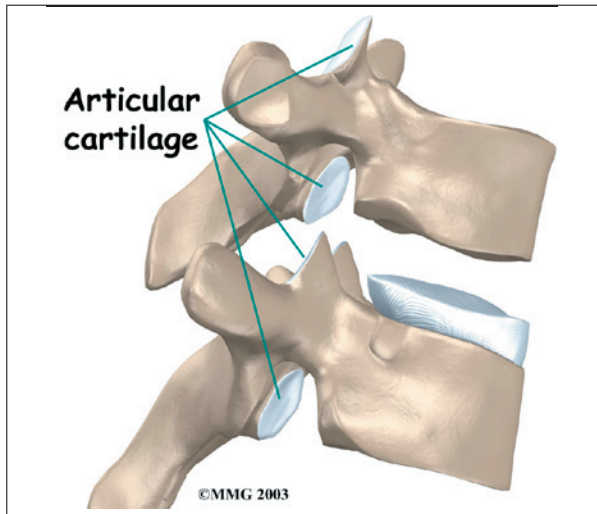
Between the vertebrae of each spinal segment are two *facet joints*. **The facet joints** are located on the back of the spinal column. There are two facet joints between each pair of vertebrae, one on each side of the spine. A facet joint is made of small, bony knobs that line up along the back of the spine. Where these knobs meet, they form a joint that



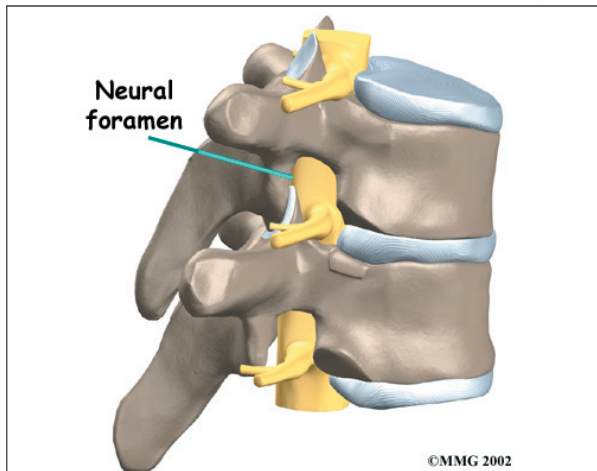


connects the two vertebrae. The alignment of the facet joints of the thoracic spine allows freedom of movement as you twist back and forth or lean side to side.

The surfaces of the facet joints are covered by **articular cartilage**. Articular cartilage is a slick, rubbery material that covers the ends of most joints. It allows the ends of bones to move against each other smoothly, without friction.



On the left and right side of each vertebra is a small tunnel called a **neural foramen**. (*Foramina* is the plural term.) The two nerves that leave the spine at each vertebra go through the foramina, one on the left and one on the right. The *intervertebral disc* (described later) sits directly in front of the opening. A



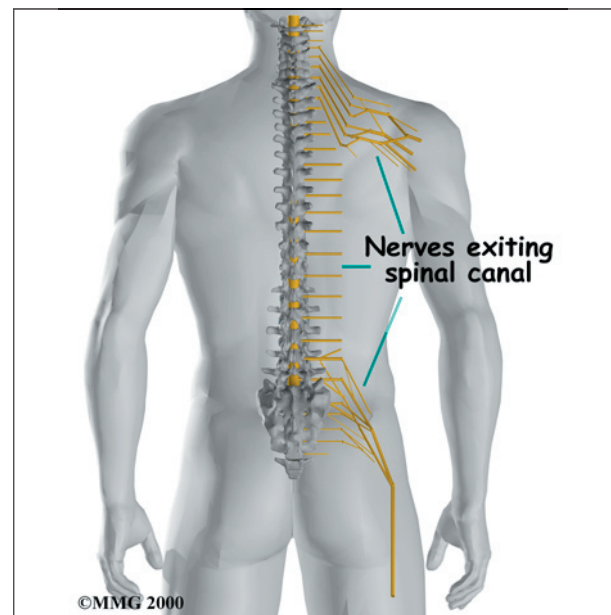
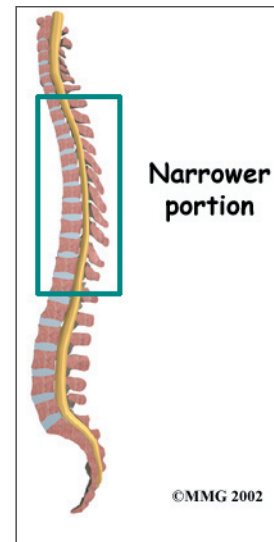
bulged or herniated disc can narrow the opening and put pressure on the nerve. A facet joint sits in back of the foramen. Bone spurs that form on the facet joint can project into the tunnel, narrowing the hole and pinching the nerve.

### Nerves

The hollow tube formed by the bony rings on the back of the spinal column surrounds the *spinal cord*. The spinal cord is like a long wire made up of millions of nerve fibers. Just as the skull protects the brain, the bones of the spinal column protect the spinal cord.

The spinal cord travels down from the brain through the spinal column. In the thoracic spine, the spinal canal is **narrower** than in the rest of the spine, giving very little extra space for the spinal cord as it passes through the thoracic spine.

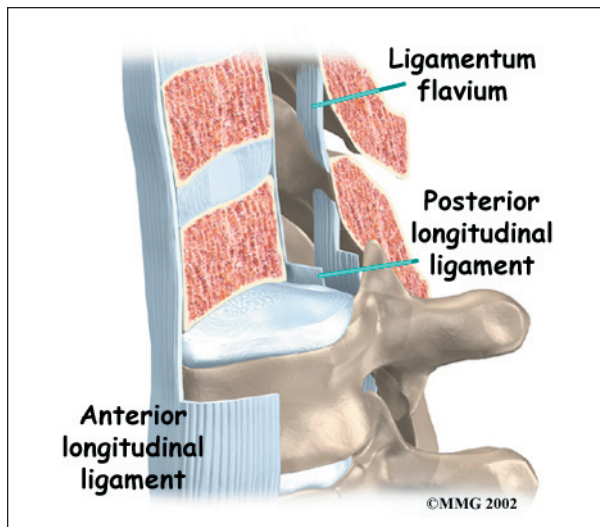
Between the vertebrae, two large **nerves** branch off the spinal cord, one on the left and one on the right. The nerves pass through the



neural foramina of each vertebra. These spinal nerves group together to form the main nerves that go to the organs and limbs. The nerves of the thoracic spine mainly control the muscles and organs of the chest and abdomen.

### Connective Tissues

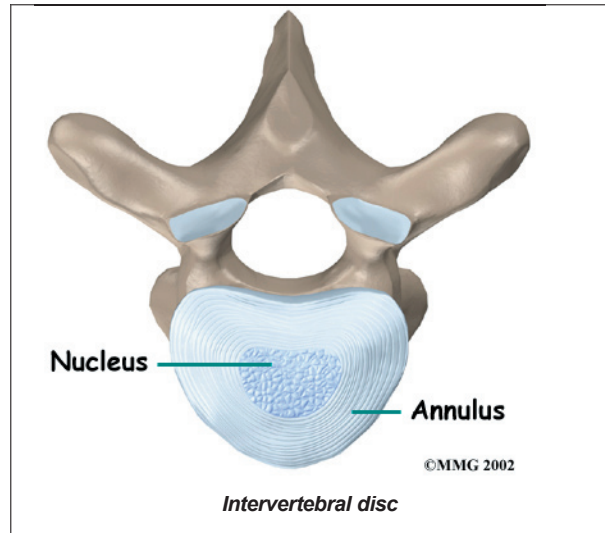
Connective tissues are networks of fiber that hold the cells of the body together. *Ligaments* are strong connective tissues that attach bones to other bones. Several long ligaments connect on the front and back sections of the vertebrae.



The *anterior longitudinal ligament* runs lengthwise down the front of the vertebral bodies. Two other ligaments run full length within the spinal canal. The *posterior longitudinal ligament* attaches on the back of the vertebral bodies. The *ligamentum flavum* is a long elastic band that connects to the front surface of the lamina bones. Thick ligaments also connect the ribs to the transverse processes of the thoracic spine.

A special type of structure in the spine called an *intervertebral disc* is also made of connective tissue. The fibers of the disc are formed by special cells, called *collagen cells*. The fibers may be lined up like strands of nylon rope or crisscrossed like a net.

An intervertebral disc is made of two parts. The center, called the *nucleus*, is spongy. It provides most of the shock absorption in the

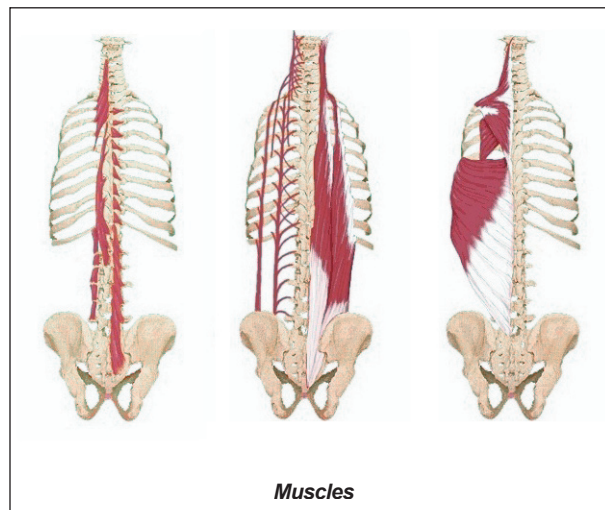


spine. The nucleus is held in place by the *annulus*, a series of strong ligament rings surrounding it.

Discs in the thoracic spine are much thinner than in the cervical and lumbar spine. As a result, there is generally less movement between the vertebrae of the thoracic spine.

### Muscles

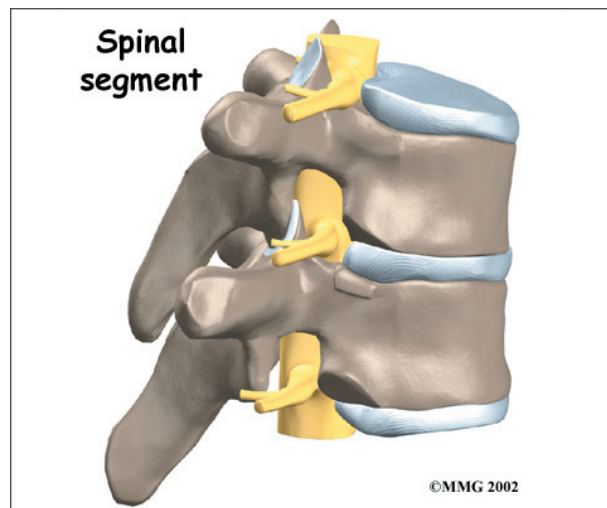
The **muscles** of the thoracic spine are arranged in layers. Those closest to the skin's surface run from the back of the vertebrae to the



shoulder blades. Others wrap around the rib cage and connect to the shoulders. Strap-shaped muscles called *erector spinae* make up the middle layer of muscles. These muscles run up and down over the lower ribs and *thorax* (the rib cage), and cross to the low back. The deepest layer of muscles attaches along the back of the spine bones, connecting the vertebrae. Muscles also connect from one rib to the next.

### **Spinal Segment**

A good way to understand the anatomy of the thoracic spine is by looking at a *spinal segment*. Each spinal segment includes two vertebrae separated by an intervertebral disc, the nerves that leave the spinal column at each vertebra, and the small facet joints that link each level of the spinal column.



### **Summary**

Many important parts make up the anatomy of the thoracic spine. Understanding the regions and structures of the thoracic spine can help you become more involved in your health care and better able to care for your back problem.

## Notes