

A Patient's Guide to **Transient Synovitis of the Hip in Children**



©MMG 2005

 **Summit**
Orthopaedics
208-227-1100

Summit Orthopedics
2321 Coronado
Idaho Falls, ID 83404
Phone: 208-227-1100
jdenny@summitortho.net



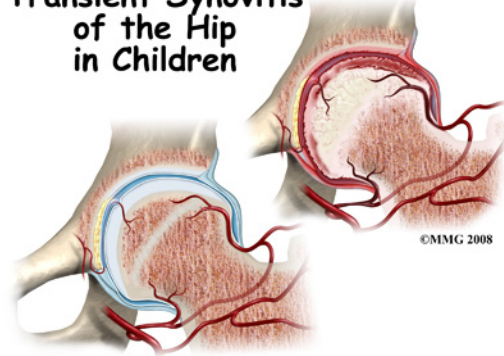
Summit Orthopedics



Summit Orthopedics
2321 Coronado
Idaho Falls, ID 83404
Phone: 208-227-1100
jdenny@summitortho.net
<http://www.summitortho.net/>

All materials within these pages are the sole property of Mosaic Medical Group, LLC and are used herein by permission. eOrthopod is a registered trademark of Mosaic Medical Group, LLC.

Transient Synovitis of the Hip in Children



Introduction

Transient synovitis of the hip is an acute inflammatory condition of the inner lining of the hip. Transient means it is temporary and doesn't last long. Transient synovitis is also known as *toxic synovitis* or *irritable hip*.

This condition affects young children (boys more than girls) most often. In fact, it's the most common cause of acute hip pain in young children between the ages of three and 10. However, there are reports of transient synovitis in children less than one year old and in adults.

This guide will help you understand

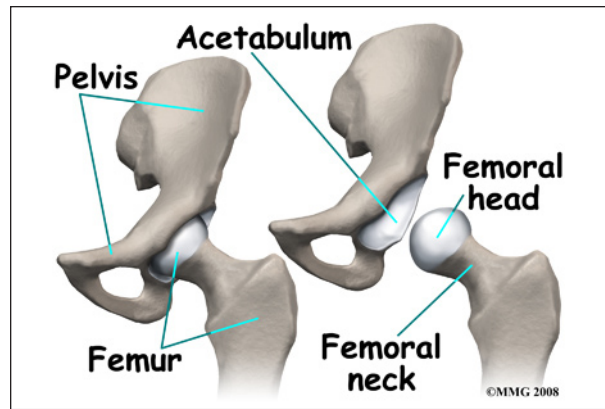
- how the condition develops
- how doctors diagnose the condition
- what treatment options are available

Anatomy

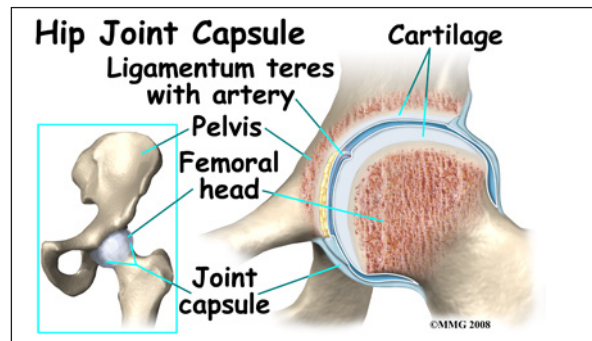
What part of the hip is affected?

The hip joint is a true ball-and-socket joint. The bones of the hip are the *femur* (the thigh-bone) and the *pelvis*. The top end of the femur is shaped like a ball. This ball is called the *femoral head*. The femoral head fits into a round socket on the side of the pelvis. This socket is called the *acetabulum*.

Transient synovitis affects the inner lining of the hip joint including the *synovium* and *joint*



capsule. The synovium is a membrane that seals the synovial fluid in the joint to lubricate the joint surface. It is between the articular cartilage and the *joint capsule*. A joint capsule is a watertight sac that surrounds a joint. In the hip, the joint capsule is formed by a group of three strong ligaments that connect the femoral head to the acetabulum. These ligaments are the main source of stability for the hip. They help hold the hip in place.



Articular cartilage is the material that covers the ends of the bones of any joint. Articular cartilage is about one-quarter of an inch thick in the large, weight-bearing joints like the hip. In the hip, articular cartilage covers the end of the femur and the socket portion of the acetabulum in the pelvis. The cartilage is especially thick in the back part of the socket, as this is where most of the force occurs during walking and running.

Articular cartilage is white and shiny and has a rubbery consistency. It is slippery, which allows the joint surfaces to slide against one another without causing any damage. The function of articular cartilage is to absorb

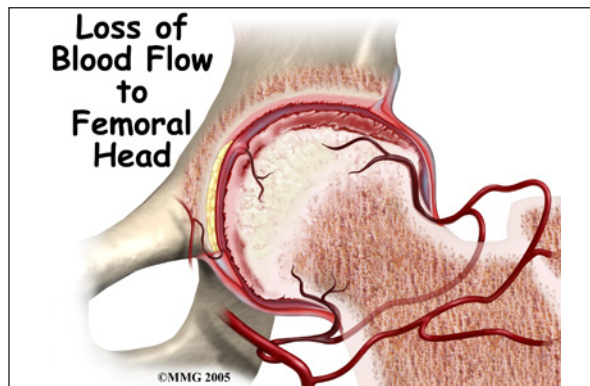
shock and provide an extremely smooth surface to make motion easier. We have articular cartilage essentially everywhere that two bony surfaces move against one another, or *articulate*.

Causes

How did this problem develop?

The exact cause of this problem is unknown. In some cases, it may develop after a recent viral infection (such as a cold or upper respiratory infection). In a smaller number of children, trauma to the hip is followed by transient synovitis.

There is much debate about a possible link between transient synovitis and another condition called *Legg-Calvé-Perthes disease*. In Perthes disease, the blood supply to the growth center of the hip (the *capital femoral epiphysis*) is disturbed, causing the bone in this area to die. The blood supply eventually returns, and the bone heals.



Only a small number of children with transient synovitis develop Legg-Calvé-Perthes disease. It's possible the prolonged increase in pressure inside the joint causes loss of blood supply to the hip. Some experts suspect children who develop Perthes disease may have undetected transient synovitis before collapse of the femoral head occurs.

Symptoms

What are the symptoms?

Inflammation and *effusion* (swelling) can cause sudden hip pain. Usually only one hip is involved. The child may refuse to walk or may limp when walking as the first sign of a problem. Younger children who aren't walking yet stop crawling or change the way they get around. They may cry at night or when having the diaper changed.

Your child may have a slight fever. A high fever is usually a sign of something more serious such as *septic arthritis* (bacterial infection of the hip) or *osteomyelitis* (bone infection).

In all age groups, there is usually a loss of hip motion. The child doesn't want to put weight on that leg. The painful symptoms may travel to the thigh, groin, or knee on the same side. Sometimes there isn't hip pain but just groin, thigh, or knee pain.

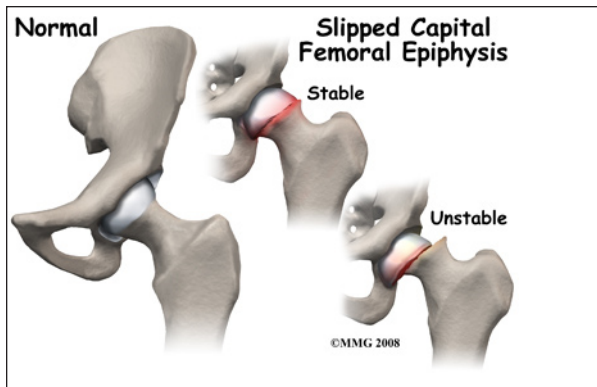
Your child may want to keep the hip and leg in a resting position of *flexion* (bent), *external rotation* (turned outward), and *abduction* (away from the other leg). This position opens up the joint capsule helps reduce the pain by taking pressure off the soft tissue structures.

Diagnosis

How do doctors diagnose the condition?

The history and physical examination are probably the most important tools the physician uses to diagnose transient synovitis of the hip. Motion is usually limited and painful. The hip is tender to palpation.

X-rays are usually taken. Though radiographs don't show synovitis, they do help the physician rule out a fracture, tumor, or *slipped capital femoral epiphysis* (slippage of the growth plate). More advanced



imaging such as MRI or bone scan may be needed if there is a need to rule out other more serious problems.

A blood test will show mild inflammation. If needed, the physician may order an ultrasound of the hip. This test will show any *effusion* (fluid collection) in the hip joint. Drawing the fluid out with a needle called *needle aspiration* will show if there is pus in the joint from *septic* (bacterial) arthritis. The fluid is clear in transient synovitis.

Treatment

What treatment options are available?

Nonsurgical Treatment

Home treatment with rest and anti-inflammatory drugs are the main treatment techniques. It is okay if your child keeps the leg turned out. Any position that is comfortable will help the healing process. The child is usually already limiting how much weight is put on that leg. If not, every effort should be made to avoid weight-bearing.

Vigorous physical activities such as running, jumping, and participating in sports activities should be avoided during the acute phase. Your physician will let you know if crutches are needed to help limit weight-bearing through that leg. If crutches are advised, they will only be needed for a few weeks.

Surgery

Surgery is not usually necessary. In severe cases of transient synovitis children may be hospitalized for observation and leg traction. Applying pull on the hip through the leg can reduce the pressure inside the joint capsule. If the child is cooperative, home traction may be possible.

Rehabilitation

What can be expected after treatment?

Nonsurgical Rehabilitation

A rehab program isn't usually needed. Most of the time, this condition *resolves* (goes away) within a week or two. The child will naturally start to increase activity as he or she starts to feel better. The condition can come back. If this happens, it will most often occur during the first six months after it first appears.

Follow-up with the physician is important. If the symptoms aren't improved or improving after seven to 10 days, then contact your child's physician. There could be something else wrong with your child's hip. Further diagnostic testing may be required. Even if your child has recovered fully, a repeat X-ray is advised. This should be done about six months after the first episode occurs. It will help identify any early signs of Legg-Calvé-Perthes disease.

Notes