

A Patient's Guide to **Dropped Head Syndrome**



©MMG 2003




Summit Orthopedics



Summit Orthopedics
2321 Coronado
Idaho Falls, ID 83404
Phone: 208-227-1100
jdenny@summitortho.net
<http://www.summitortho.net/>

All materials within these pages are the sole property of Mosaic Medical Group, LLC and are used herein by permission. eOrthopod is a registered trademark of Mosaic Medical Group, LLC.



Dropped Head Syndrome

Introduction

Dropped Head Syndrome is characterized by severe weakness of the muscles of the back of the neck. This causes the chin to rest on the chest in standing or sitting. *Floppy Head Syndrome* and *Head Ptosis* are other names used to describe the syndrome.

Most of the time, Dropped Head Syndrome is caused by a specific generalized neuromuscular diagnosis. When the cause is not known, it is called *isolated neck extensor myopathy*, or INEM.

This guide will help you understand

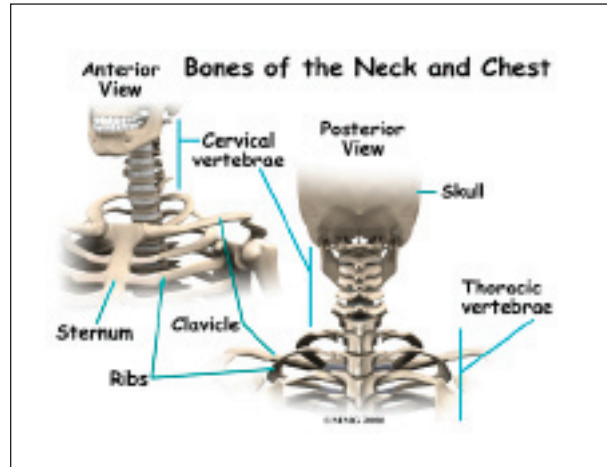
- what parts make up the cervical spine
- what causes this condition
- how doctors diagnose this condition
- what treatment options are available

Anatomy

What parts make up the cervical spine?

The spine is made up of a column of bones. Each bone, or *vertebra*, is formed by a round block of bone, called a *vertebral body*. A bony ring attaches to the back of the vertebral body, forming a canal for the spinal cord. The spinal cord is made up of nerve cells which grow to look like a rope or cord about one half inch in diameter. The spinal cord attaches to the base

of the brain. The base of the brain is called the *brainstem*.



The vertebral column is divided into three distinct portions. The *cervical*, or neck portion attaches to the base of the skull at the upper end. The lower end of the cervical portion connects with the *thoracic* spine. There are seven cervical vertebrae.

There are many muscles that lie in the neck region. Some attach from the base of the skull, others to the spine, ribs, collar bone, and shoulder blade. *Extension* of the neck happens when the top of the head tilts backward. This causes the face and eyes to look up. *Flexion* of the neck is when the top of the head tilts forward. This causes the eyes to look down. It also lowers the chin to the chest.

The vertebrae stack on top of one another. When looking at the spine from the side, or from the *sagittal view*, the vertebral column is not straight up and down, but forms an *S* curve. The cervical spine has an inward curve called a *lordosis*. The thoracic spine curves outward. This curve is called a *kyphosis*. The lumbar spine usually has an inward curve or a *lordosis*. The *S* curve seen in the *sagittal* or side view allows for shock-absorption and acts as a spring when the spine is loaded with weight.

Causes

What causes this condition?

Most of the time, Dropped Head Syndrome is caused by a specific generalized neuromuscular diagnosis. These include *amyotrophic lateral sclerosis* (ALS) also known as Lou Gehrig's disease, Parkinson's disease, myasthenia gravis, polymyositis, and genetic myopathies. Other specific causes can include motor neuron disease, hypothyroidism, disorders of the spine, and cancer.

When the cause of Dropped Head Syndrome is not known, it is called *isolated neck extensor myopathy*, or INEM.

The INEM form of Dropped Head Syndrome usually happens in older persons. The weakness of the muscles in the back of the neck usually occurs gradually over one week to three months.

Symptoms

What does this condition feel like?



The symptoms of Dropped Head Syndrome are usually painless. It most often occurs in the elderly. The weakness is limited to the muscles that extend the neck. Dropped Head Syndrome usually develops over a period of one week to three months. The head is then tilted downward. Because of the weakness of the extensors of the neck, the chin rests on the chest. Lifting or raising the head in sitting or standing is impossible. When lying down however, the neck is able to extend.

Gaze is down at the floor, instead of forward. The face is downward. The neck appears elongated, and the curve at the base of the neck is accentuated. This can cause over stretching or pinching of the spinal cord. When this happens, there may be weakness and numbness of the arms or entire body.

Dropped head syndrome can also cause difficulty swallowing, speaking, and breathing.

Diagnosis

How will my doctor diagnose the condition?

Diagnosis begins with a complete history and physical exam. Your doctor will ask questions about your symptoms and how your problem is affecting your daily activities.

Your doctor will do a physical examination to test your reflexes, skin sensation, muscle strength.

Most of the time, loss of neck extension occurs as part of a more generalized neurological disorder. Neurological conditions must be considered first because some are treatable. A neurologist will usually be involved to help decide what is causing the chin-on-chest deformity.

Your doctor will likely ask that you have *magnetic resonance imaging* (MRI) of your neck. The MRI machine uses magnetic waves rather than X-rays. It shows the anatomy of the neck. It is very good at showing the spinal cord and nerves. The test does not require a dye or a needle.

Electromyography (EMG) uses small diameter needles in the muscle belly being tested. It helps determine how well the nerve conducts signals to the muscles.

A *muscle biopsy* may be needed. A small piece of muscle is removed and examined under a microscope. A closer look at the muscle fibers can be helpful in making a diagnosis.

In isolated neck extensor myopathy (INEM), the muscle biopsy is non-specific. EMG shows some myopathic changes. Labs are normal.

If no other associated neurologic disorders are found, then the diagnosis of isolated neck extensor myopathy (INEM) is made. It is a diagnosis of *exclusion*, meaning that everything else that could cause it has been ruled out. It is not known what causes isolated neck extensor myopathy (INEM).

Some doctors feel that isolated neck extensor myopathy (INEM) is caused by either a non-specific non-inflammatory or inflammatory response that is restricted to the neck extensor muscles. Another possible cause is thoracic kyphosis. When the natural curve of the thoracic spine is increased, it may place the extensor muscles at a disadvantage given the weight of the head. This may cause overstretching and weakness of the extensor muscles.

Treatment

What treatment options are available?

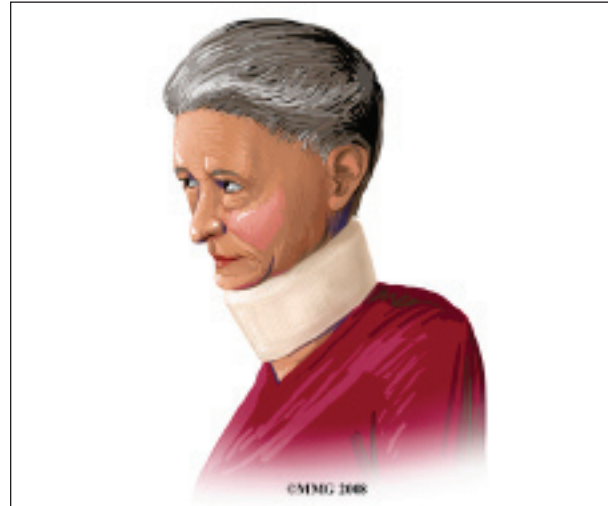Isolated neck extensor myopathy (INEM) is considered benign because it does not spread or get worse. Symptoms can improve in some cases. It is most often treated conservatively, with physical therapy and use of a neck brace.

Nonsurgical Treatment

Treatment of Dropped Head Syndrome is mainly supportive. The weakness remains localized to the neck extensor muscles. Physical therapy may help with this. There are some cases that improve dramatically, but most usually do not improve.

The most useful treatment is use of a neck collar. It can partially correct the chin-on-chest deformity. This improves the forward gaze and activities of daily living. It also can help prevent contractures of the neck in a fixed flexed posture. However, it can be uncomfortable and cause sores under the chin. Some use

a baseball cap attached to straps around the trunk. This avoids the chin discomfort from using a collar.



Prednisone is a potent anti-inflammatory that may be prescribed. It may be beneficial when there is local myositis, or inflammation of the muscles. It can be taken in a pill form by mouth or intravenously.

Surgery

Unless fusion is necessary, surgery is usually not recommended in Dropped Head Syndrome.

When there is damage to the nerves in the neck or spinal cord, surgery to fuse the neck may be necessary. This usually requires a fusion from C2-T2. The loss of neck movement after fusion leaves patients unable to see the ground in front of their feet. This makes them at greater risk for falls. The inconvenience caused by having a rigid neck may prove to be a greater problem than the original dropped head deformity.

Osteoporosis, particularly in older females also poses a problem with surgery. The soft bone may allow the metal used to stabilize the spine to pull out.

Rehabilitation

What should I expect after treatment?

Nonsurgical Rehabilitation

Physical therapy is usually recommended. Neck extension strengthening exercises may provide some improvement. However, most patients will find the strengthening both tiring and frustrating. When lying down on your back you can move the neck to maintain range of motion. This helps to avoid unnecessary stiffness and shortening of the muscles in the front of the neck.

Range of motion exercises should be done on an ongoing basis to avoid contractures of the neck. Wearing a neck collar when up will likely improve activities of daily living.

Speech therapy may be recommended for swallowing, feeding, and breathing problems. Some people may need to have a feeding tube inserted through the stomach.

Your doctor may want to repeat imaging of the spine. There is the possibility of overstretching or pinching the spinal cord when the neck extensors are so weak. You will need to watch for symptoms such as weakness or numbness in the arms or other portions of the body. Bowel and bladder function could become a problem.

After Surgery

If surgery is recommended, you will probably require an overnight hospital stay or a few days stay. Initially, you will not be allowed to lift, and you will have to move carefully. Most likely your neck will be placed in a fairly rigid brace. You will eventually be able to resume your normal activities. You can expect healing of the fusion in three to nine months.

Physical therapy is usually recommended after surgery. Neck extension strengthening exercises are prescribed to prevent contracture of the neck. Occupational therapy may be recommended to help with arm strengthening. It can also help with dressing, and other activities of daily living. Equipment needs can be evaluated by the occupational therapist. Speech therapy

may also be recommended after surgery.

Your surgeon will want to follow up with you on a regular basis. Imaging studies may need to be repeated on occasion. Assessment of the fusion is usually done with X-rays.

Notes