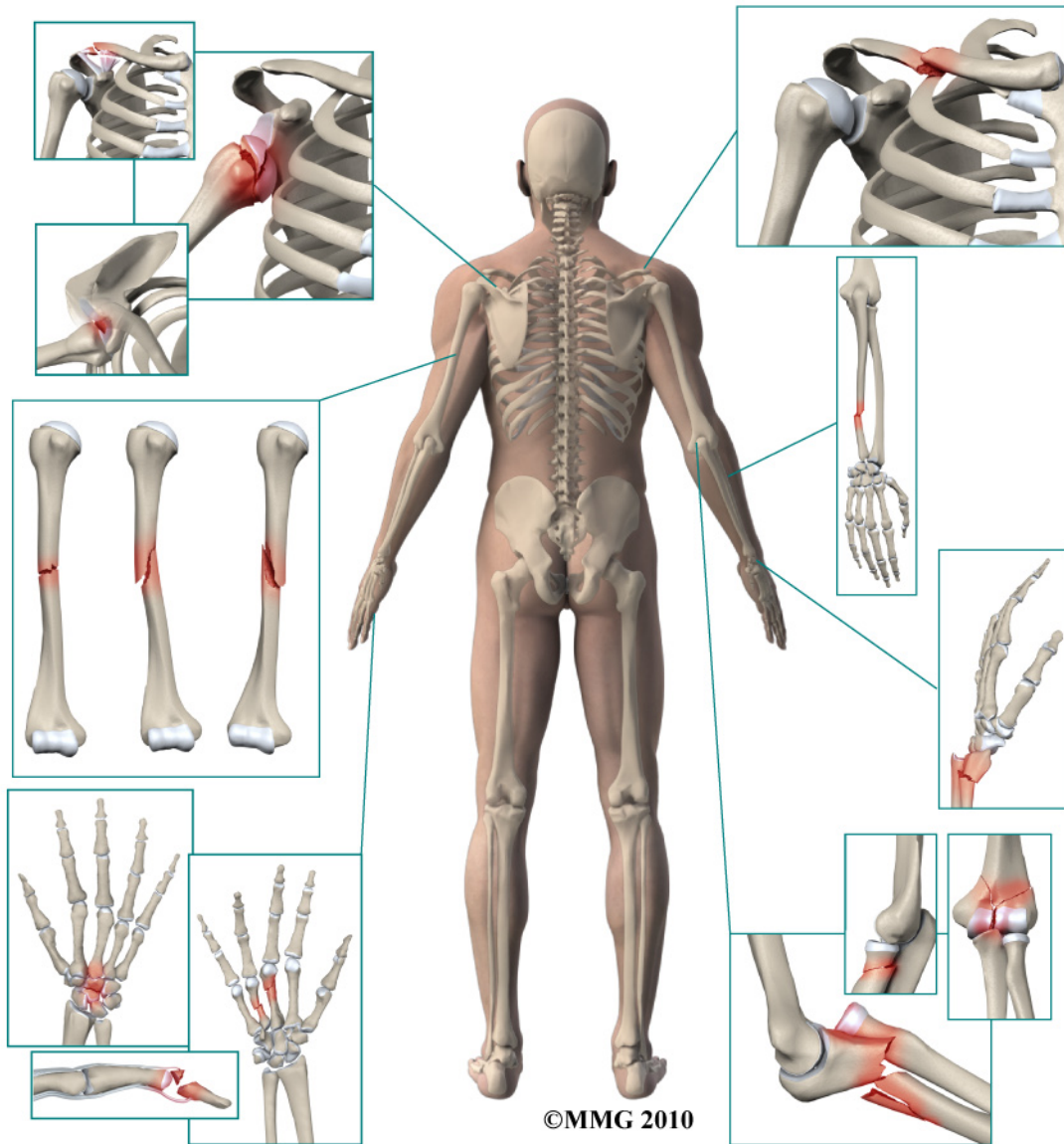


A Patient's Guide to Adult Humerus Shaft Fractures



TJN TCHEJAYAN Dr. Gregory H. Tchejeyan
ORTHOPAEDICS
& SPORTS MEDICINE



TJN TCHEJAYAN
ORTHOPAEDICS
& SPORTS MEDICINE

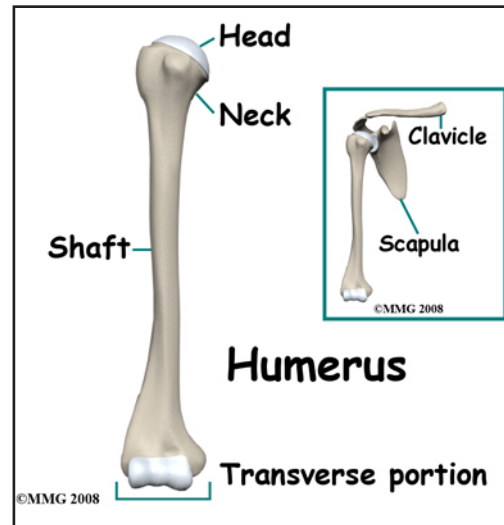
Dr. Gregory H. Tchejeyan
250 Lombard Street Ste 1
Thousand Oaks, CA 91360
Phone: 805-495-3687 Fax: 805-494-1828
<http://tjnortho.com>

All materials within these pages are the sole property of Mosaic Medical Group, LLC and are used herein by permission. eOrthopod is a registered trademark of Mosaic Medical Group, LLC.

Adult Humerus Shaft Fractures

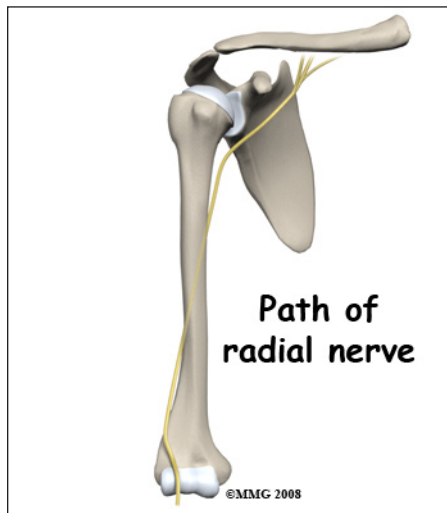
Anatomy

The *humerus* is the long, tubular bone that makes up the upper arm. The *humeral shaft* is the middle portion of the bone with the shoulder joint at the top end and the elbow joint at the bottom. One of the nerves that travels from the neck to the hand, the *radial nerve*, spirals around the humeral shaft lying very close to the bone about two thirds of the way to the elbow. Fractures of the humeral shaft are important because they can injure the radial nerve resulting in the inability to *extend* (bend) the wrist and fingers backwards.



Signs and Symptoms

A fracture of the humeral shaft causes pain in the upper



arm. You will probably not be able to raise the arm and the arm will have a tendency to flop and bend. There is usually bleeding from the fracture into the tissues of the upper arm. Significant swelling commonly occurs from the shoulder to the hand. You may feel the bone fragments shift as you move.

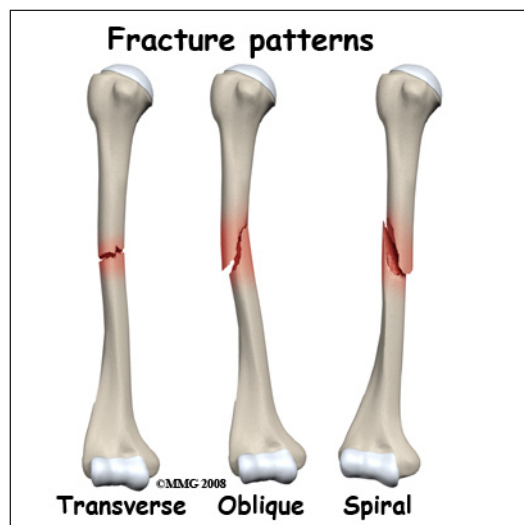
Evaluation

The primary goal of the clinical evaluation of a humeral shaft fracture is to decide how the fracture can be treated - with or without surgery - and to evaluate whether there has been damage to the radial nerve. The fracture is evaluated by taking several x-rays of the upper arm that include the elbow joint and shoulder joint. Special imaging studies such as a CAT Scan or

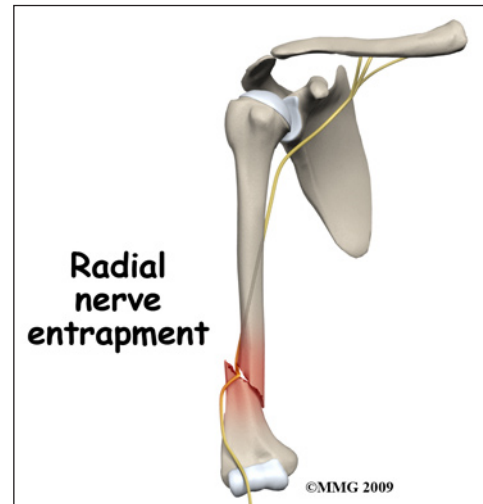
MRI Scan are usually unnecessary. Your provider will also want to make sure that there has been no damage to the radial nerve. This can usually be accomplished with a careful physical examination.

Treatment

There are several factors that determine whether your surgeon will suggest treating the fracture with or without surgery. The surgeon must first decide if the fracture can be reduced to acceptable alignment and held there without surgery. Other factors will be considered including your age, general health, whether

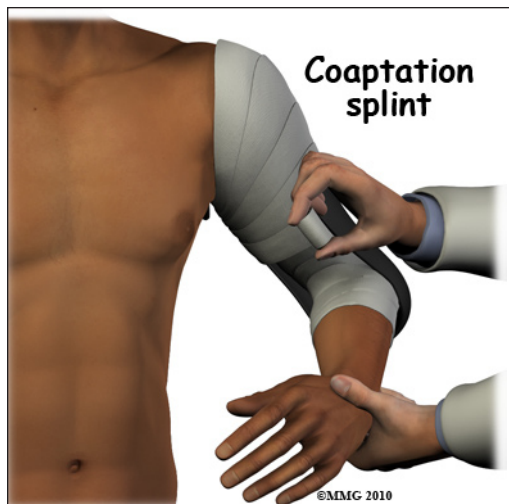


you have osteoporosis and whether this is your dominant arm. If the fracture is an *open* fracture (also called a "compound" fracture) surgery will be necessary. An open fracture occurs when there is a laceration through the skin that connects to the fracture. This can be caused by either the ends of the fracture tearing out through the skin or an external object puncturing the skin from the outside. Your surgeon must balance the risks and benefits of both surgical and non-surgical treatment, discuss these risks and benefits with you and choose the method that seems to be most appropriate to both of you.

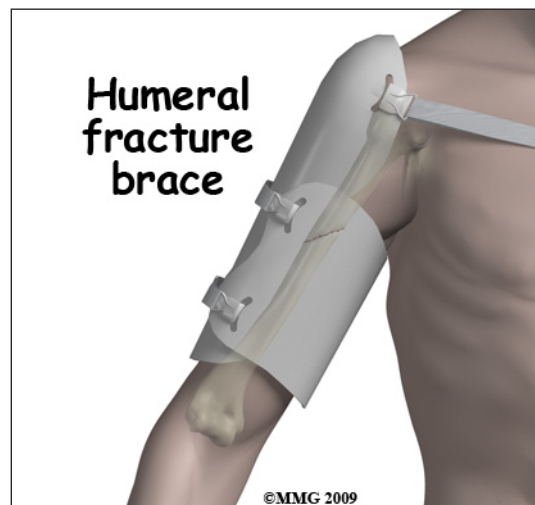
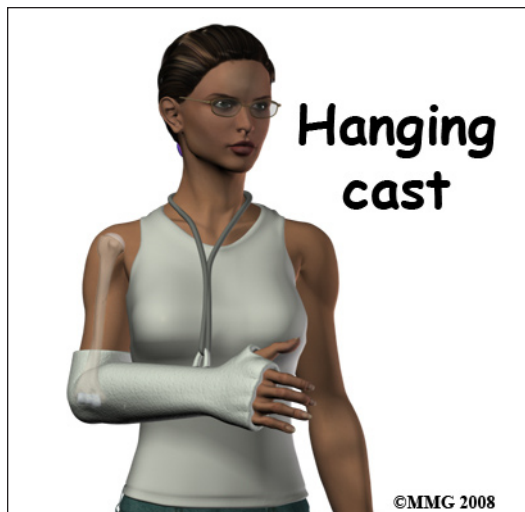
Nonsurgical

Humeral fractures are commonly treated without surgery. If your provider makes the assessment that the fracture will heal and give you good arm function without surgery, non-surgical treatment will be recommended. Initially the fracture may be treated with a special type of splint called a *coaptation splint*.



The splint is used to hold the fracture still until the swelling and pain subsides. The splint may be changed to either a hanging cast or a special fracture brace after one to two weeks. Both the hanging arm cast and the fracture brace allow the arm to hang by the side; the weight of the arm (and the cast) provides traction that aligns the bone fragments as they heal. You may have to sleep in a recliner for several weeks to allow the weight of the arm to continue to provide traction as you sleep. You may feel the bone fragments shift as you move; this usually stops by the third week after the fracture.

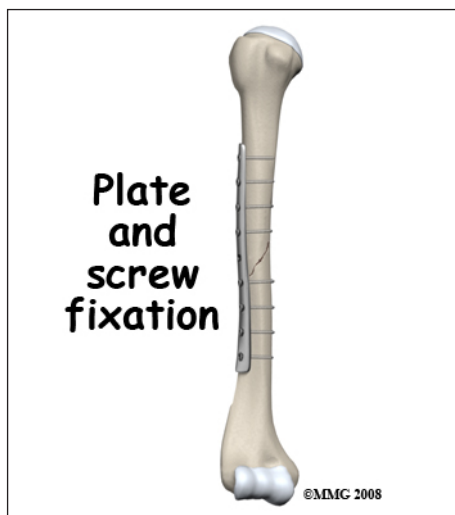
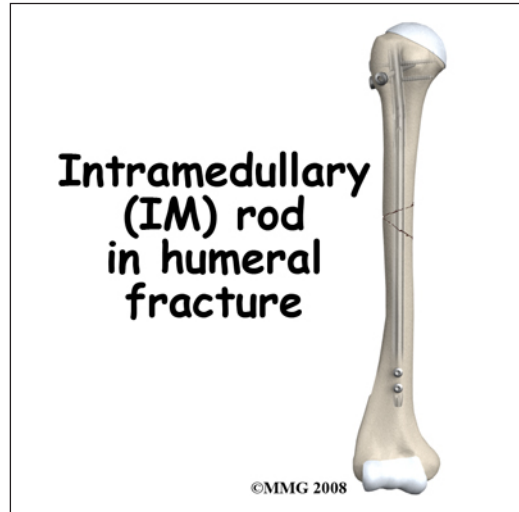


Surgery

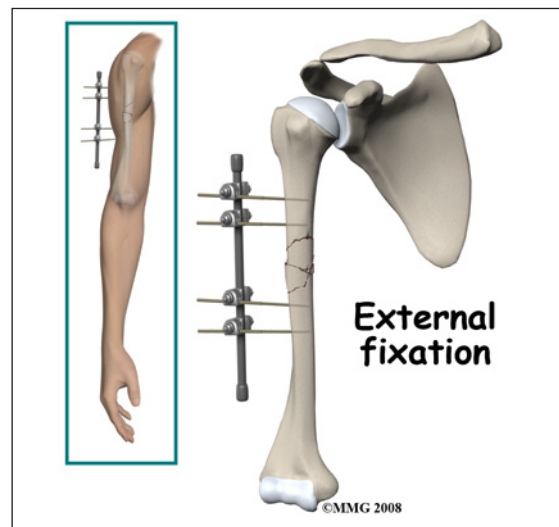
Humeral shaft fractures may need surgery. If your provider makes the assessment that the fracture will NOT heal and give you good arm function without surgery, surgical treatment will be recommended. If the fracture cannot be held in acceptable position with a hanging cast or fracture brace, surgery may be suggested after several days or weeks of attempting non-surgical treatment. If the radial nerve was working during the initial evaluation but stops working after treatment by closed reduction, your surgeon may need to perform surgery to make sure that the radial nerve has not become trapped between the bone fragments of the fracture. If exploration of the radial nerve becomes necessary, the fracture will be fixed surgically as well.

Surgical treatment of humeral shaft fractures can be performed in three ways: a metal rod inside the bone (*intramedullary rod*), a metal plate and screws along the side of the bone, or an *external fixator* with metal pins through the skin.

The intramedullary rod is commonly used to treat humeral shaft fractures. The intramedullary rod is a long metal rod that is placed inside the hollow shaft of a tubular bone such as the humerus. The metal rod can be inserted into the humerus through a small incision at the shoulder. In some cases, the rod is inserted at the elbow. The intramedullary rod is inserted with the aid of a special X-ray machine called a fluoroscope. The fluoroscope allows the surgeon to see an X-ray image of the bones on a television monitor and guide the placement of the intramedullary rod by viewing this image.



Open Reduction and Internal Fixation (ORIF) of humeral shaft fractures using a metal plate and screws is also very common. This type of treatment requires a relatively large incision. ORIF with a plate and screws is usually the treatment of choice when the Radial nerve must be explored, since an incision will need to be made to expose the fracture anyway.

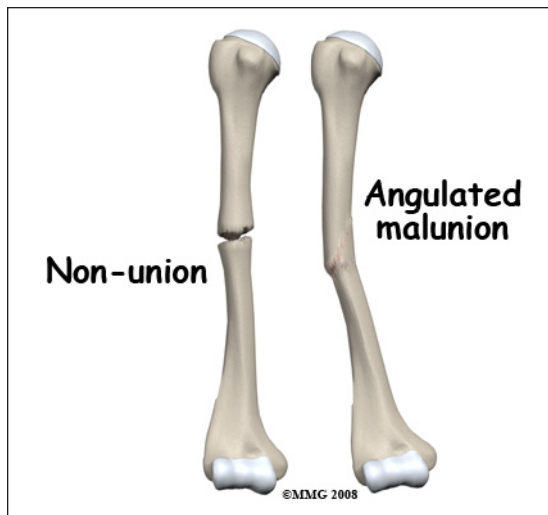
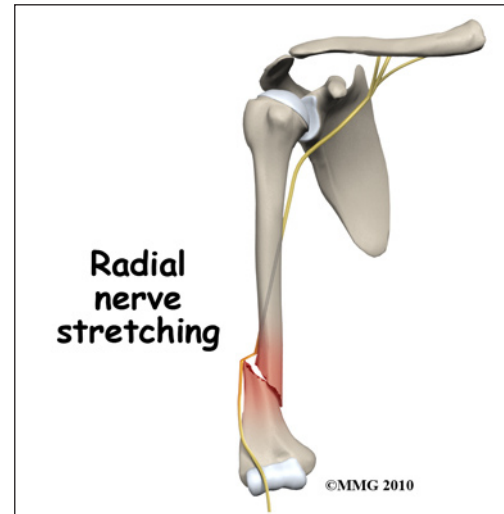

External fixation is not commonly used for humeral shaft fractures. This type of treatment may be necessary for open fractures when the risk of infection is

high. The external fixation device allows the surgeon to place metal pins through the skin and into the bone fragments away from the fracture site. These metal pins are then connected to a metal frame *outside the skin*. The fracture is stabilized, but there are no foreign materials (such as metal plates) in the fracture site to harbor the infectious bacteria. The fracture is less likely to develop *osteomyelitis*, an infection of the bone.

Complications

Nearly all fractures can result in damage to nerves and blood vessels. Damage to the radial nerve is uncommon after a humeral shaft fracture, but it is one of the complications that your surgeon will watch for carefully. When the radial nerve is damaged by the fracture, this is usually temporary. The damage is caused by stretching or bruising of the nerve; the nerve remains intact. You will most likely regain radial nerve function slowly



over a period of several months. If the radial nerve injury does not heal, then a second operation may be necessary to repair the radial nerve. In some cases a *tendon transfer* may be required to regain the ability to extend your wrist.

The fracture fragments may fail to heal; this is referred to as a *nonunion*. The fracture fragments may also heal in an unacceptable alignment; this is called *malunion*. Both of these complications may result in pain, loss of strength, and a decreased range of motion of the shoulder. A second operation may be needed to treat the complication.

Rehabilitation

Humeral shaft fractures heal in about three months. During the first three to four weeks, you may feel the fracture fragments shift as you move your arm. This is normal for fractures that have not been treated with surgery. Your shoulder and elbow may become somewhat stiff because you will not be using the joints normally. Physical therapy is usually recommended to regain both strength and range of motion in the shoulder and elbow.

Rehabilitation will begin once your surgeon feels that the fracture is stable enough to begin regaining the range of motion in your shoulder and elbow. If surgery has been required, the rehabilitation program will be modified to protect the fixation of the fracture fragments. Your surgeon will communicate with your physical therapist to make sure that your rehabilitation program does not risk causing the fixation to fail. If the surgeon feels that the fixation is very solid, you may

be able progress your program quickly; if the fixation is not so solid, the speed at which you progress may need to be slowed until more healing occurs.

The prognosis for humeral shaft fractures is generally excellent. The humeral shaft is covered by thick muscles. The shoulder has the largest range of motion of any joint in the body. What this means is that even if the fracture fragments do not heal exactly in their normal position the shoulder joint can easily compensate and provide you with a well functioning arm and the bulk of the arm generally hides any residual angulation in the humerus.

NOTE: For further information about fractures visit www.eOrthopod.com

Notes