

## *A Patient's Guide to* **Ankle Anatomy**



©MMG 2003

**Zehr Center for Orthopaedics**  
2659 Professional Circle  
Suite 1110  
Naples, FL 34119  
Phone: 239-596-0100 Fax: 239-596-6737

## Zehr Center for Orthopaedics



Welcome to the Zehr Center for Orthopaedics in Naples, FL where we strive every day to make a difference in the lives of our patients. Our orthopaedic practice is decidedly preferred by patients with difficulties affecting their HIPS and KNEES, as these are the problem focused areas where we have our most extensive experience.

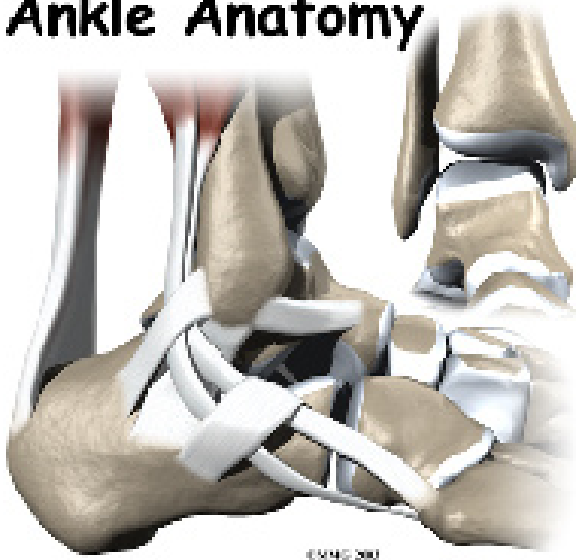
Philosophically, we want you to know that the hallmark virtues upon which our practice is founded "Wisdom, Integrity, Experience and Compassion" Inspire each member of the patient care team to reach beyond themselves to provide you the highest quality in patient care, prudent counsel, clinical expertise and most importantly-- true concern for YOU, our patient, for whom we are honored to care.

Our founder, Robert J. Zehr, MD, has dedicated his professional education and career to the research, understanding and care of some of the most complex orthopaedic problems in the field including primary and revision total joint replacement, as well as, skeletal reconstruction associated with tumors and fractures.

With the experience of over 6000 primary, revision and complex joint reconstructions to call upon, Dr. Zehr brings the most up to date surgical techniques, patient safety and knowledge of rehabilitation to each patient's surgical problem. In addition, his mastery of minimally invasive surgical techniques, rapid recovery rehab protocols and shortened hospital stays has resulted in greatly improved surgical outcomes, fewer complications and highly satisfied patients. It is our great privilege to serve you!

Zehr Center for Orthopaedics  
2659 Professional Circle  
Suite 1110  
Naples, FL 34119  
Phone: 239-596-0100 Fax: 239-596-6737  
info@zehrcenter.com  
<http://www.zehrcenter.com>

# Ankle Anatomy



## Introduction

The ankle joint acts like a hinge. But it's much more than a simple hinge joint. The ankle is actually made up of several important structures. The unique design of the ankle makes it a very stable joint. This joint has to be stable in order to withstand 1.5 times your body weight when you walk and up to eight times your body weight when you run.

Normal ankle function is needed to walk with a smooth and nearly effortless gait. The muscles, tendons, and ligaments that support the ankle joint work together to propel the body. Conditions that disturb the normal way the ankle works can make it difficult to do your activities without pain or problems.

This guide will help you understand

- what parts make up the ankle
- how the ankle works

## Important Structures

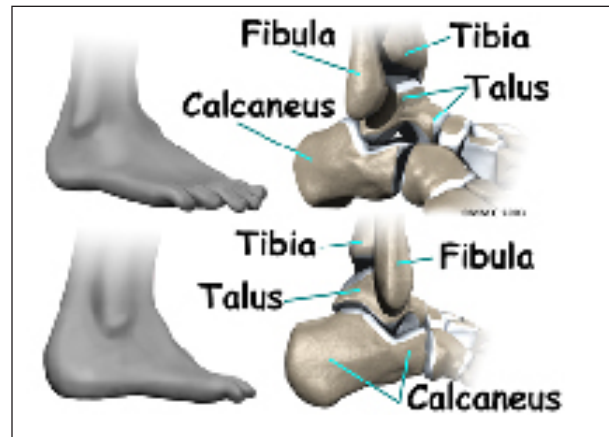
The important structures of the ankle can be divided into several categories. These include

- bones and joints
- ligaments and tendons
- muscles
- nerves
- blood vessels

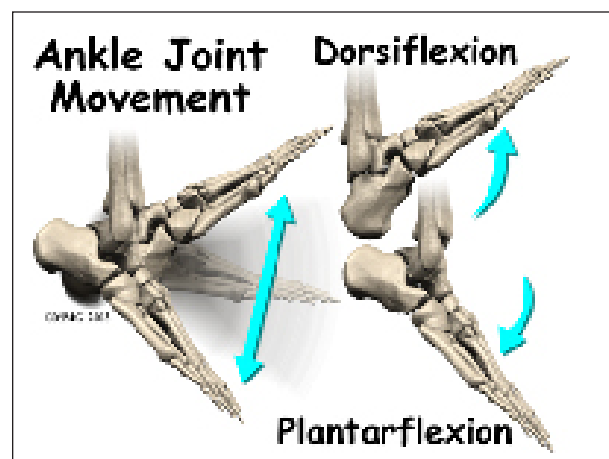
The top of the foot is referred to as the *dorsal* surface. The sole of the foot is the *plantar* surface.

## Bones and Joints

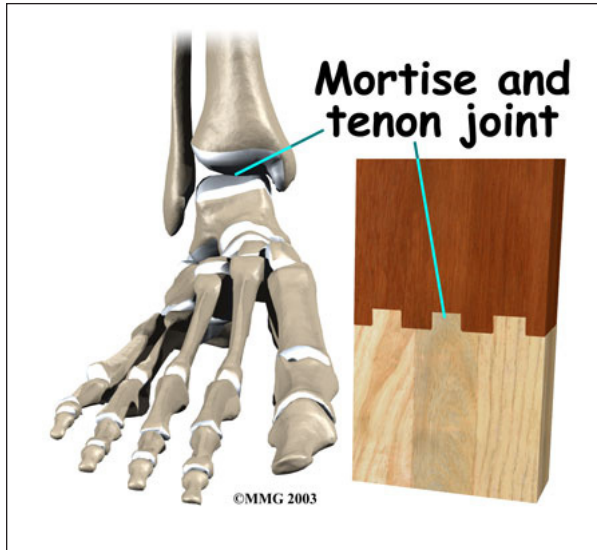
The ankle joint is formed by the connection of three bones. The ankle bone is called the *talus*. The top of the talus fits inside a socket that is formed by the lower end of the *tibia* (shinbone) and the *fibula* (the small bone of the lower leg). The bottom of the talus sits on the heelbone, called the *calcaneus*.



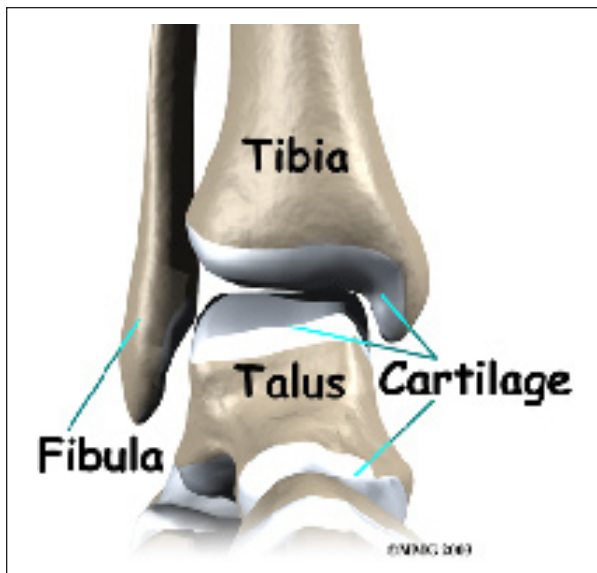
The talus works like a **hinge** inside the socket to allow your foot to move up (*dorsiflexion*) and down (*plantarflexion*).



Woodworkers and craftsmen are familiar with the design of the ankle joint. They use a similar construction, called a **mortise and tenon**, to create stable structures. They routinely use it to make strong and sturdy items, such as furniture and buildings.



Inside the joint, the bones are covered with a slick material called **articular cartilage**. Articular cartilage is the material that allows the bones to move smoothly against one another in the joints of the body.

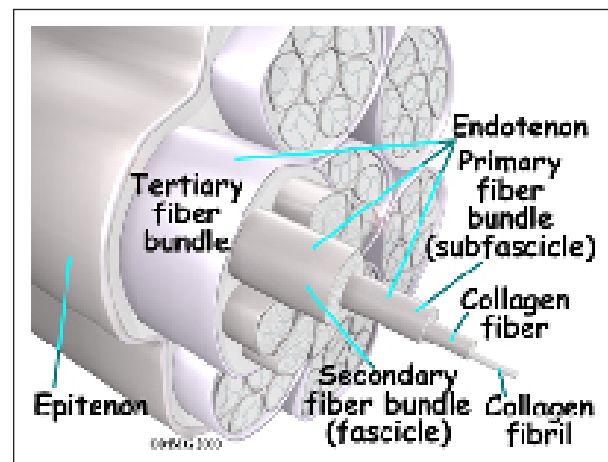


The **cartilage** lining is about one-quarter of an inch thick in most joints that carry body weight, such as the ankle, hip, or knee. It is

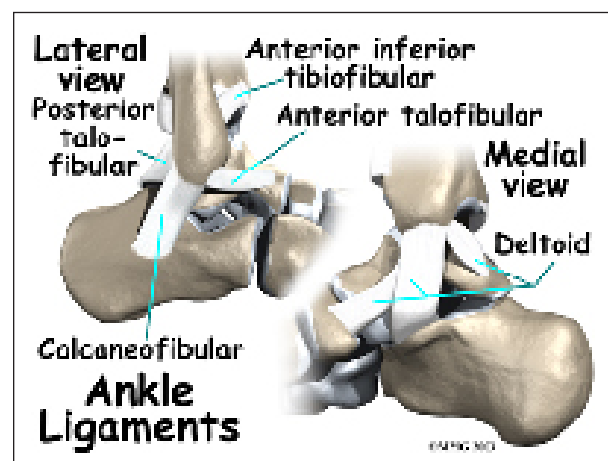
soft enough to allow for shock absorption but tough enough to last a lifetime, as long as it is not injured.

### Ligaments and Tendons

**Ligaments** are the soft tissues that attach bones to bones. Ligaments are very similar to **tendons**. The difference is that tendons attach muscles to bones. Both of these structures are made up of small fibers of a material called **collagen**. The collagen fibers are bundled together to form a rope-like structure. Ligaments and tendons come in many different sizes and, like rope, are made up of many smaller fibers. Thickness of the ligament or tendon determines its strength.

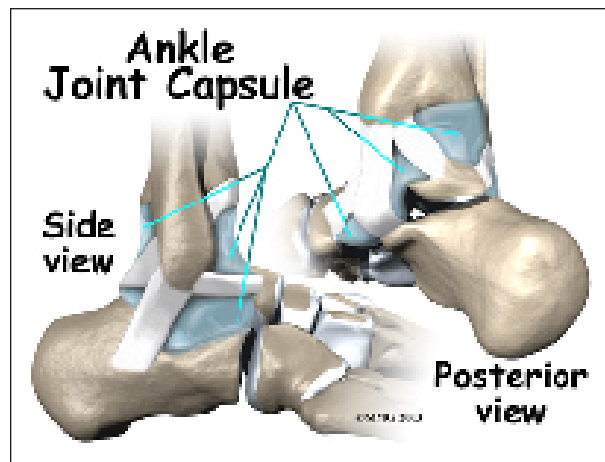


Ligaments on both sides of the ankle joint help hold the bones together. **Three ligaments** make up the **lateral ligament complex** on the side of the ankle farthest from the other ankle.

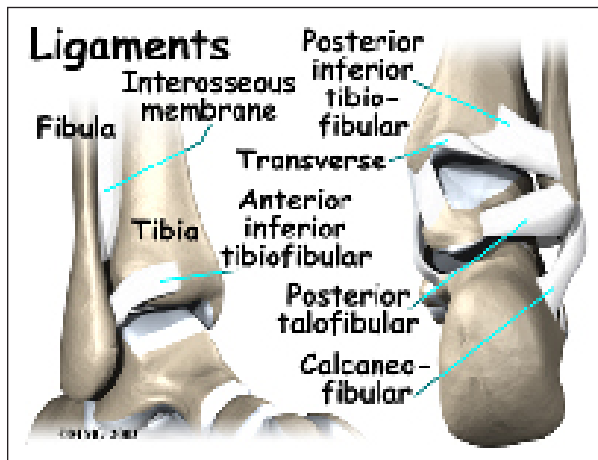


(*Lateral* means further away from the center of the body.) These include the *anterior talofibular ligament* (ATFL), the *calcaneofibular ligament* (CFL), and the *posterior talofibular ligament* (PTFL). A thick ligament, called the *deltoid ligament*, supports the medial ankle (the side closest to your other ankle).

Ligaments also support the lower end of the leg where it forms a hinge for the ankle. This series of ligaments supports the ankle *syndesmosis*, the part of the ankle where the bottom end of the fibula meets the tibia. **Three main ligaments** support this area. The ligament crossing just above the front of the ankle and connecting the tibia to the fibula is called the *anterior inferior tibiofibular ligament*

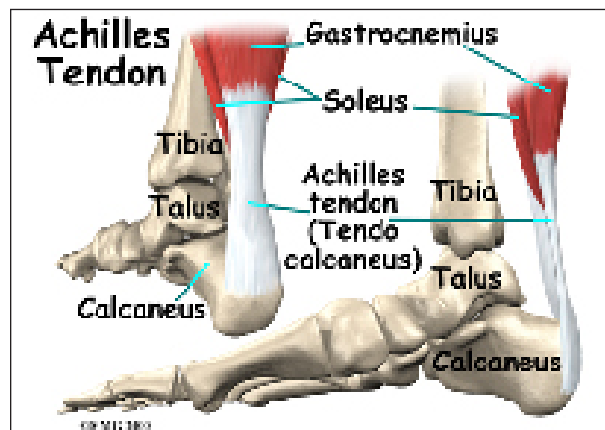


The ankle joint is also supported by nearby tendons. The large *Achilles tendon* is the most important tendon for walking, running, and jumping. It attaches the calf muscles to the

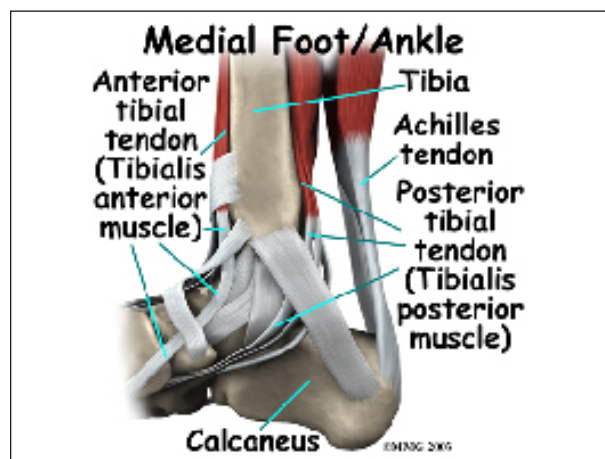


(AITFL). The *posterior fibular ligaments* attach across the back of the tibia and fibula. These ligaments include the *posterior inferior tibiofibular ligament* (PITFL) and the *transverse ligament*. The *interosseous ligament* lies between the tibia and fibula. (*Interosseous* means between bones.) The interosseous ligament is a long sheet of connective tissue that connects the entire length of the tibia and fibula, from the knee to the ankle.

The ligaments that surround the ankle joint help form part of the *joint capsule*. A joint capsule is a watertight sac that forms around all joints. It is made up of the ligaments around the joint and the soft tissues between the ligaments that fill in the gaps and form the sac.

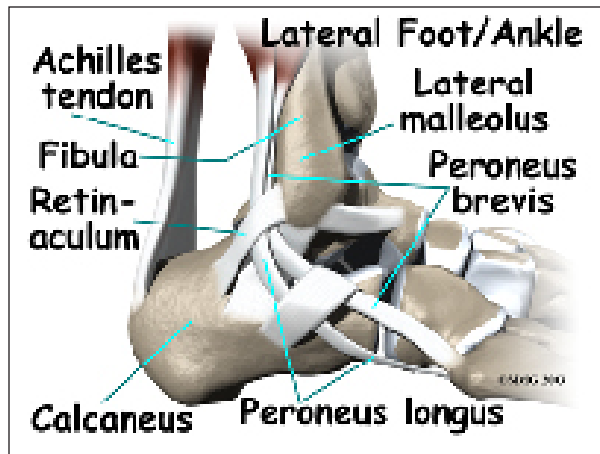


calcaneus (heelbone) and allows us to raise up on our toes. The *posterior tibial tendon* attaches one of the smaller muscles of the calf to the underside of the foot. This tendon helps support the arch and allows us to turn the foot





inward. The *anterior tibial tendon* allows us to raise the foot. Two tendons run behind the outer bump of the ankle, called the *lateral malleolus*. These two tendons, the *peroneals*, help turn the foot down and out.



### Muscles

Most of the motion of the ankle is caused by the stronger muscles in the lower leg whose tendons pass by the ankle and connect in the foot. Contraction of the muscles in the leg is the main way that we move our ankle when we walk, run, and jump.

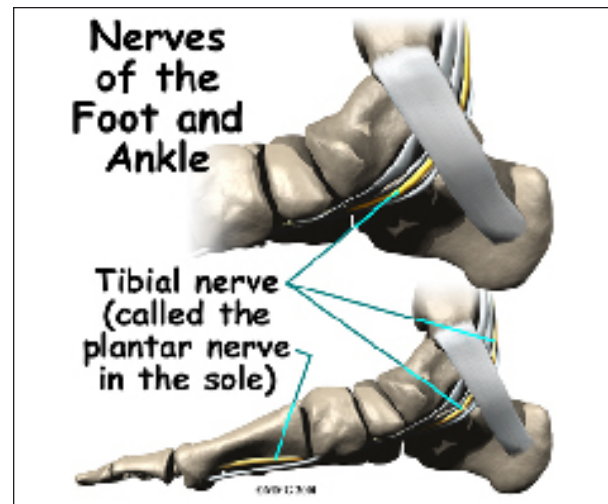
The key ankle muscles have been discussed earlier in the section on ligaments and tendons. These muscles and their actions are also listed here.

- The peroneals (*peroneus longus* and *peroneus brevis*) on the outside edge of the ankle and foot bend the ankle down and out.
- The calf muscles (*gastrocnemius* and *soleus*) connect to the calcaneus by the Achilles tendon. When the calf muscles tighten, they bend the ankle down.
- The posterior tibialis muscle supports the arch and helps turn the foot inward.
- The anterior tibialis pulls the ankle upward.

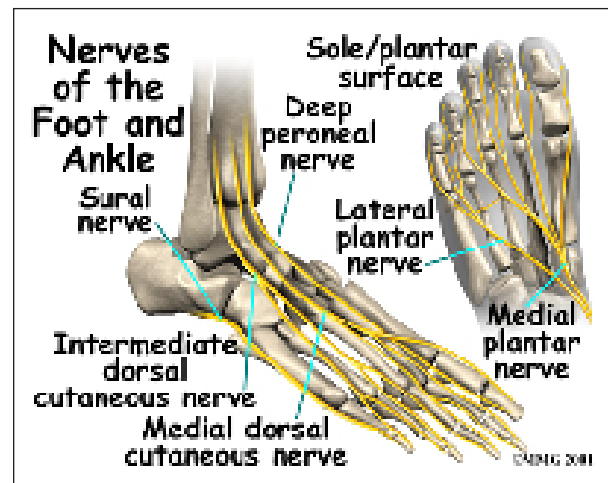
### Nerves

The nerve supply of the ankle is from nerves that pass by the ankle on their way into the

foot. The *tibial nerve* runs behind the medial malleolus. Another nerve crosses in front of

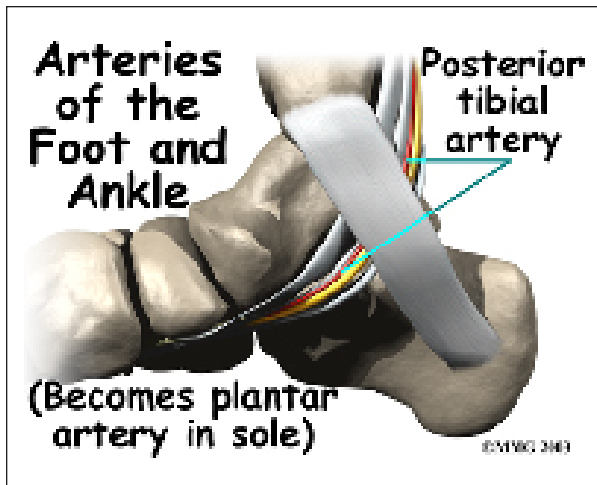


the ankle on its way to top of the foot. There is also a nerve that passes along the outer edge of the ankle. The nerves on the **front and outer edge** of the ankle control the muscles in this area, and they give sensation to the top and outside edge of the foot.

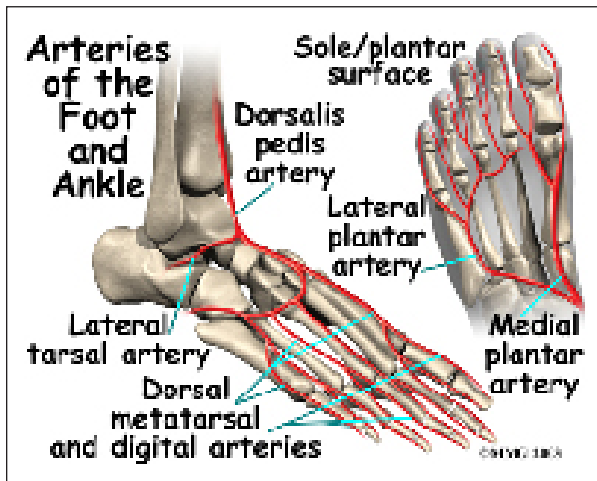


### Blood Vessels

The ankle gets blood from nearby arteries that pass by the ankle on their way to the foot. The *dorsalis pedis* runs in front of the ankle to the top of the foot. (You can feel your pulse where this artery runs in the middle of the top of the foot.) Another large artery, called the *posterior tibial artery*, runs behind the medial malleolus. It sends smaller blood vessels to the inside



edge of the ankle joint. Other less important arteries entering the foot from other directions also supply blood to the ankle.



### Summary

As you can see, the anatomy of the ankle is very complex. When everything works together, the ankle functions correctly. When one part becomes damaged, it can affect every other part of the ankle and foot, leading to problems.

## Notes