

## *A Patient's Guide to* **Lumbar Spine Anatomy**



©MMG 200.



**Centre for Orthopaedics**  
**Suite 10-33/34/35 Mount Elizabeth Novena Specialist**  
**Centre**  
**38 Irrawaddy Road**  
**Singapore, 329563**



## Centre for Orthopaedics


Please take the time to explore our web office. Discover all we have to offer. We hope you will find the time spent on our website rewarding and informative. Here at the Centre for Orthopaedics, we are dedicated to providing ways for those we serve to access the information needed to make informed decisions about healthcare in orthopaedic and sports medicine.

We encourage you to explore our site and learn more about our practice, staff, facilities and treatment options. Check out the Patient Resources section of our site. You will find educational materials to help you understand orthopaedic problems and what options for treatment are available in our clinic.

The Staff of the Centre for Orthopaedics.



Centre for Orthopaedics  
Suite 10-33/34/35 Mount Elizabeth Novena Specialist Centre  
38 Irrawaddy Road  
Singapore, 329563  
Phone: (65) 6684 5828 Fax: (65) 6684 5829  
sharon@cfo.com.sg  
<http://www.cfo.com.sg>



**Lumbar Spine Anatomy**

©MMG 2002

**Introduction**

Knowing the main parts of your low back and how these parts work is important as you learn to care for your back problem. This guide gives a general overview of the anatomy of the low back.

Two common anatomic terms are useful as they relate to the low back. The term *anterior* refers to the front of the spine. The term *posterior* refers to the back of the spine. The section of the spine that makes up the low back is called the *lumbar spine*. The front of the low back is therefore called the *anterior lumbar area*. The back of the lower spine is called the *posterior lumbar area*.

**This guide gives a general overview of the anatomy of the low back. It should help you understand**

- what parts make up the low back
- how these parts work

### Important Structures

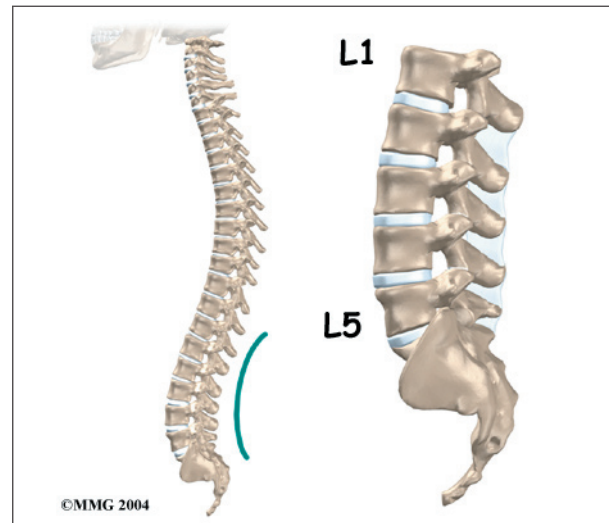
The important parts of the lumbar spine include

- bones and joints
- nerves
- connective tissues
- muscles
- spinal segments

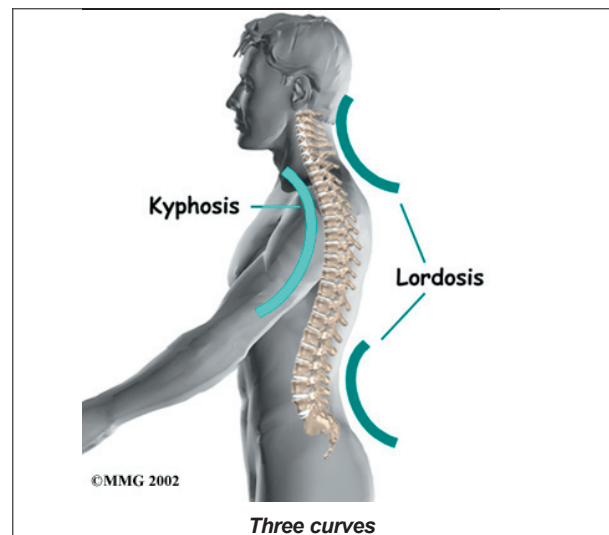
This section highlights important structures in each category.

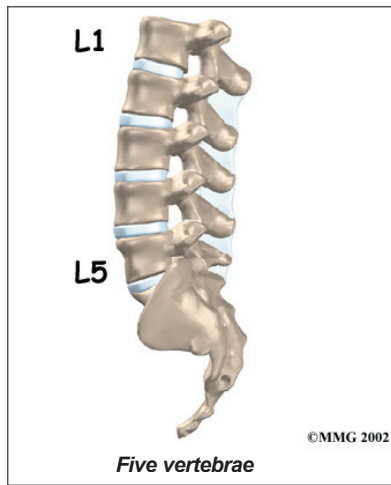
### Bones and Joints

The **human spine** is made up of 24 spinal bones, called *vertebrae*. Vertebrae are stacked on top of one another to form the spinal column. The spinal column is the body's main upright support.



From the side, the spine forms **three curves**. The neck, called the *cervical spine*, curves slightly inward. The middle back, or *thoracic spine*, curves outward. The outward curve of the thoracic spine is called *kyphosis*. The low back, also called the *lumbar spine*, curves slightly inward. An inward curve of the spine is called *lordosis*.



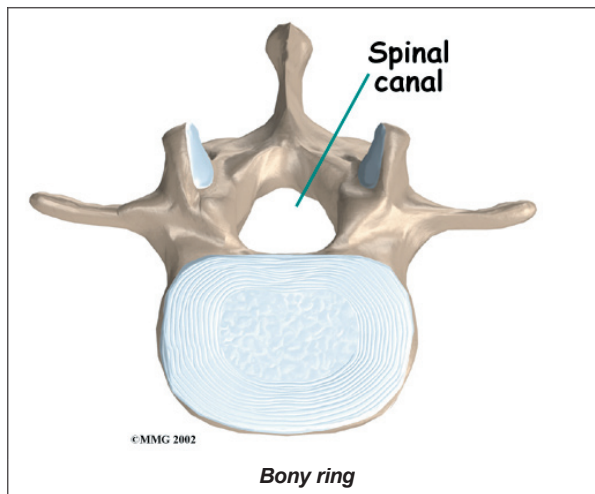


The lumbar spine is made up of the lower **five vertebrae**. Doctors often refer to these vertebrae as L1 to L5. The lowest vertebra of the lumbar spine, L5, connects to

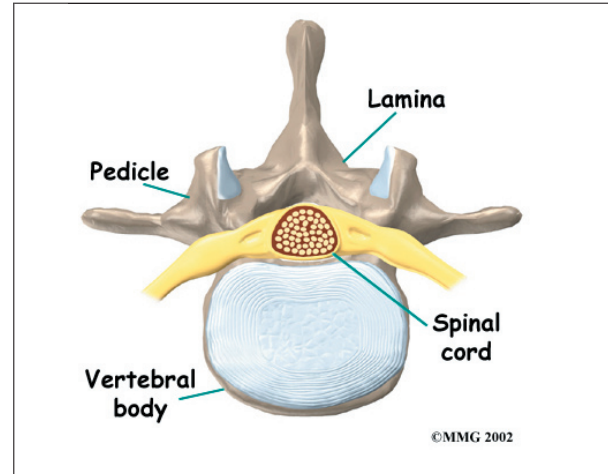
the top of the *sacrum*, a triangular bone at the base of the spine that fits between the two pelvic bones. Some people have an extra, or sixth, lumbar vertebra. This condition doesn't usually cause any particular problems.

Each vertebra is formed by a round block of bone, called a *vertebral body*. The lumbar vertebral bodies are taller and bulkier compared to the rest of the spine. This is partly because the low back has to withstand pressure from body weight and from movements such as lifting, carrying, and twisting. Also, large and powerful muscles attaching on or near the lumbar spine place extra force on the lumbar vertebral bodies.

A **bony ring** attaches to the back of each vertebral body. This ring has two parts. Two **pedicle bones** connect directly to the back of

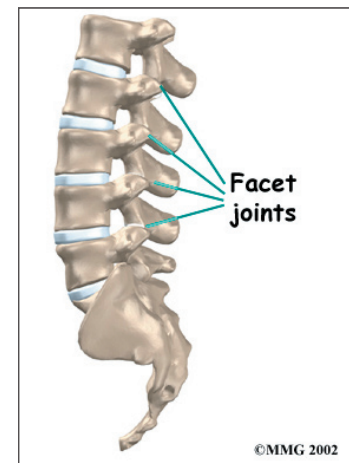


the vertebral body. Two *lamina bones* join the pedicles to complete the ring. The lamina bones form the outer rim of the bony ring. When the vertebrae are stacked on top of each other, the bony rings form a hollow tube that surrounds the **spinal cord** and nerves. The laminae provide a protective roof over these nerve tissues.



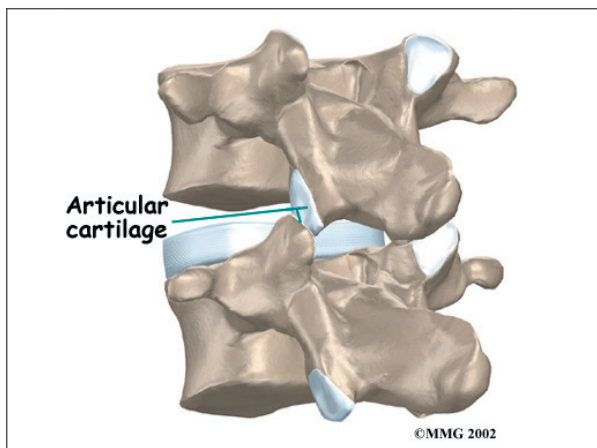
A bony knob projects out at the point where the two lamina bones join together at the back of the spine. These projections, called *spinous processes*, can be felt as you rub your fingers up and down the back of your spine. Each vertebra also has two bony knobs that point out to the side, one on the left and one on the right. These bony projections are called *transverse processes*. The projections in the low back are broader than in other areas of the spine because many large back muscles attach and impart powerful forces on them.

Between the vertebrae of each spinal segment are two **facet joints**. The facet joints are located on the back of the spinal column. There are two facet joints between each pair of vertebrae, one



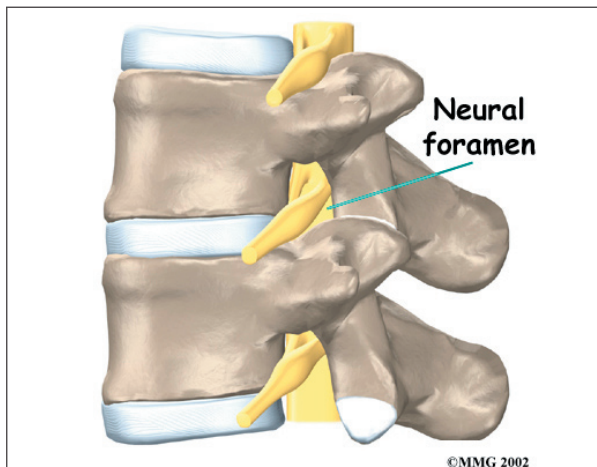
on each side of the spine. A facet joint is made of small, bony knobs that line up along the back of the spine. Where these knobs meet, they form a joint that connects the two vertebrae. The alignment of the facet joints of the lumbar spine allows freedom of movement as you bend forward and back.

The surfaces of the facet joints are covered by **articular cartilage**. Articular cartilage is a smooth, rubbery material that covers the ends of most joints. It allows the ends of bones to move against each other smoothly, without friction.



### Neural Foramina

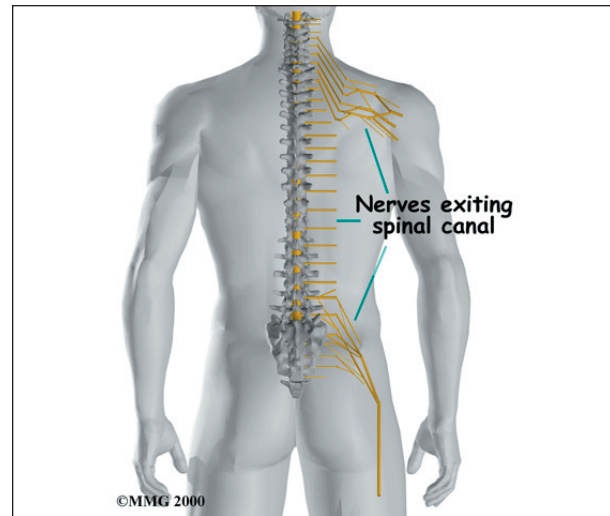
On the left and right side of each vertebra is a small tunnel called a **neural foramen**. (*Foramina* is the plural term.) The two nerves that leave the spine at each vertebra go through the foramina, one on the left and one on the



right. The intervertebral disc (described later) sits directly in front of the opening. A bulged or herniated disc can narrow the opening and put pressure on the nerve. A facet joint sits in back of the foramen. Bone spurs that form on the facet joint can project into the tunnel, narrowing the hole and pinching the nerve.

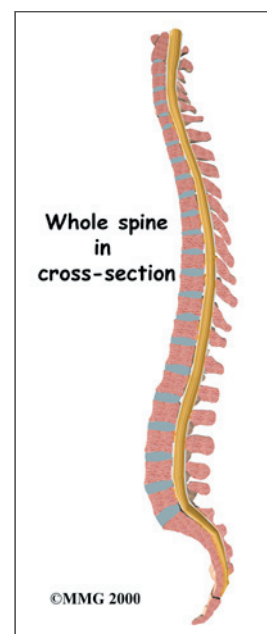
### Nerves

The hollow tube formed by the bony rings on the back of the spinal column surrounds the **spinal cord**. The spinal cord is like a long wire made up of millions of nerve fibers. Just as the skull protects the brain, the bones of the spinal column protect the spinal cord.



The spinal cord extends down to the L2 vertebra. Below this level, the spinal canal encloses a bundle of nerves that goes to the lower limbs and pelvic organs. The Latin term for this bundle of nerves is *cauda equina*, meaning *horse's tail*.

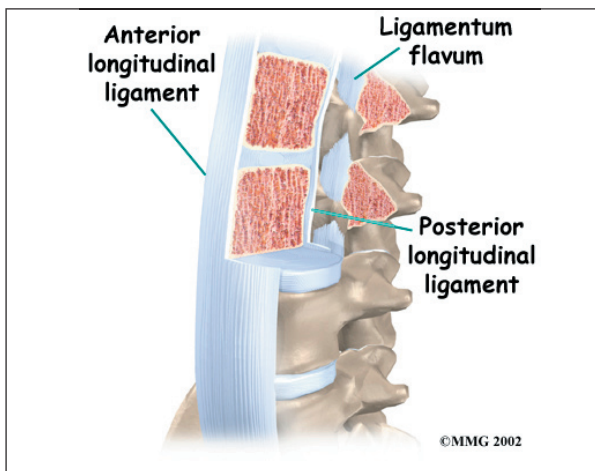
Between vertebrae, two large nerves branch off the spinal cord, one on the left and one on



the right. The nerves pass through the neural foramina of each vertebra. These spinal nerves group together to form the main nerves that go to the organs and limbs. The nerves of the lumbar spine (cauda equina) go to the pelvic organs and lower limbs.

### Connective Tissues

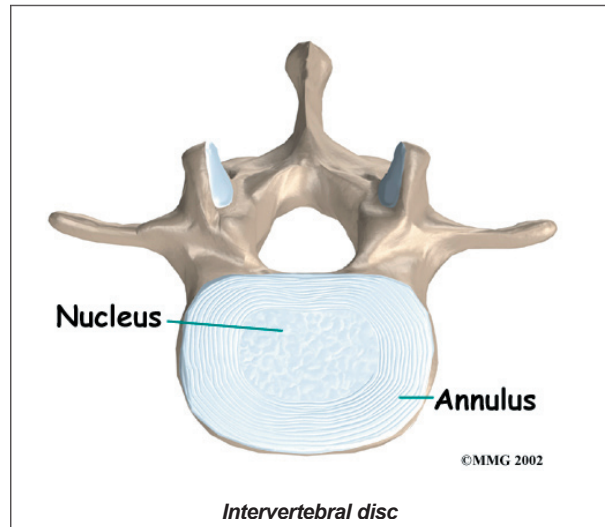
*Connective tissues* are networks of fiber that hold the cells of the body together. *Ligaments* are strong connective tissues that attach bones to other bones. **Several long ligaments** connect on the front and back sections of the vertebrae. The *anterior longitudinal ligament* runs lengthwise down the front of the vertebral bodies. Two other ligaments run full-length within the spinal canal. The *posterior longitudinal ligament* attaches on the back of the vertebral bodies. The *ligamentum flavum* is a long elastic band that connects to the front surface of the lamina bones (just behind the spinal cord). Thick ligaments also connect the bones of the lumbar spine to the sacrum (the bone below L5) and pelvis.



A special type of structure in the spine called an *intervertebral disc* is also made of connective tissue. The fibers of the disc are formed by special cells, called *collagen cells*. The fibers may be lined up like strands of nylon rope or crisscrossed like a net.

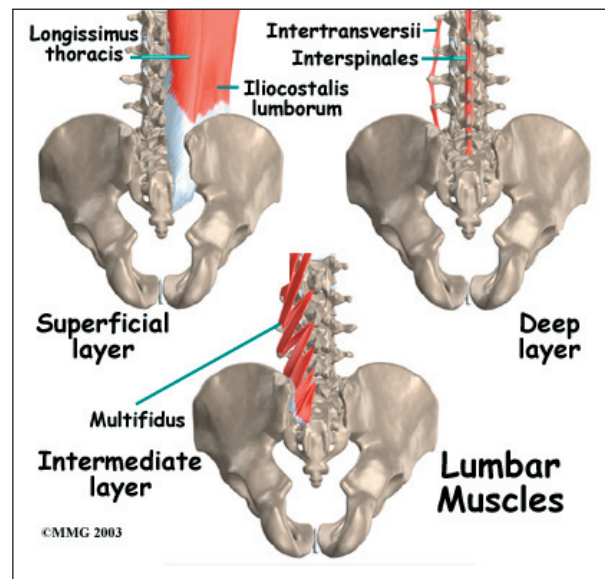
An intervertebral disc is made of two parts. The center, called the *nucleus*, is spongy. It

provides most of the shock absorption in the spine. The nucleus is held in place by the *annulus*, a series of strong ligament rings surrounding it.



### Muscles

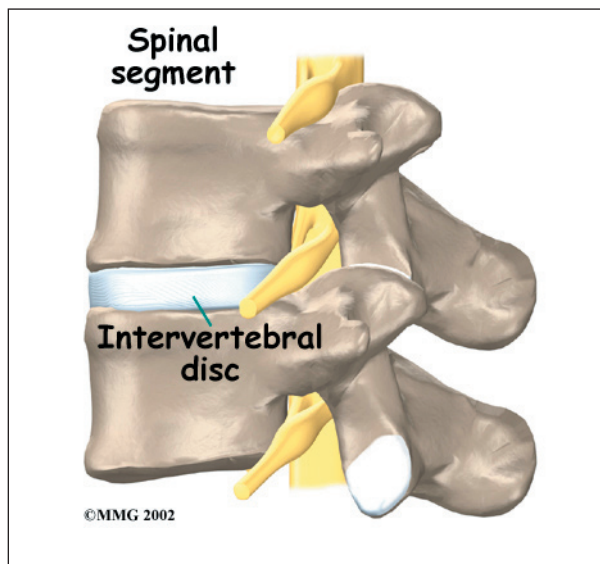
The **muscles** of the low back are arranged in layers. Those closest to the skin's surface, the superficial layer, are covered by a thick tissue called *fascia*. The middle layer, called the *erector spinae*, has strap-shaped muscles that run up and down over the lower ribs, chest, and low back. They join in the lumbar spine to form a thick tendon that binds the bones of the low back, pelvis, and sacrum. The deepest layer of muscles attaches along the



back surface of the spine bones, connecting the low back, pelvis, and sacrum. These deepest muscles coordinate their actions with the muscles of the abdomen to help hold the spine steady during activity.

## Spinal Segment

A good way to understand the anatomy of the lumbar spine is by looking at a *spinal segment*. Each spinal segment includes two vertebrae separated by an intervertebral disc, the nerves that leave the spinal column at each vertebra, and the small facet joints that link each level of the spinal column.



The intervertebral disc separates the two vertebral bodies of the spinal segment. The disc normally works like a shock absorber. It protects the spine against the daily pull of gravity. It also protects the spine during heavy activities that put strong force on the spine, such as jumping, running, and lifting.

The spinal segment is connected by two facet joints, described earlier. When the facet joints of the lumbar spine move together, they bend and turn the low back.

## Summary

Many important parts make up the anatomy of the back. Understanding the regions and structures of the lumbar spine can help you be more involved in your health care and better able to care for your back problem.

## **Notes**