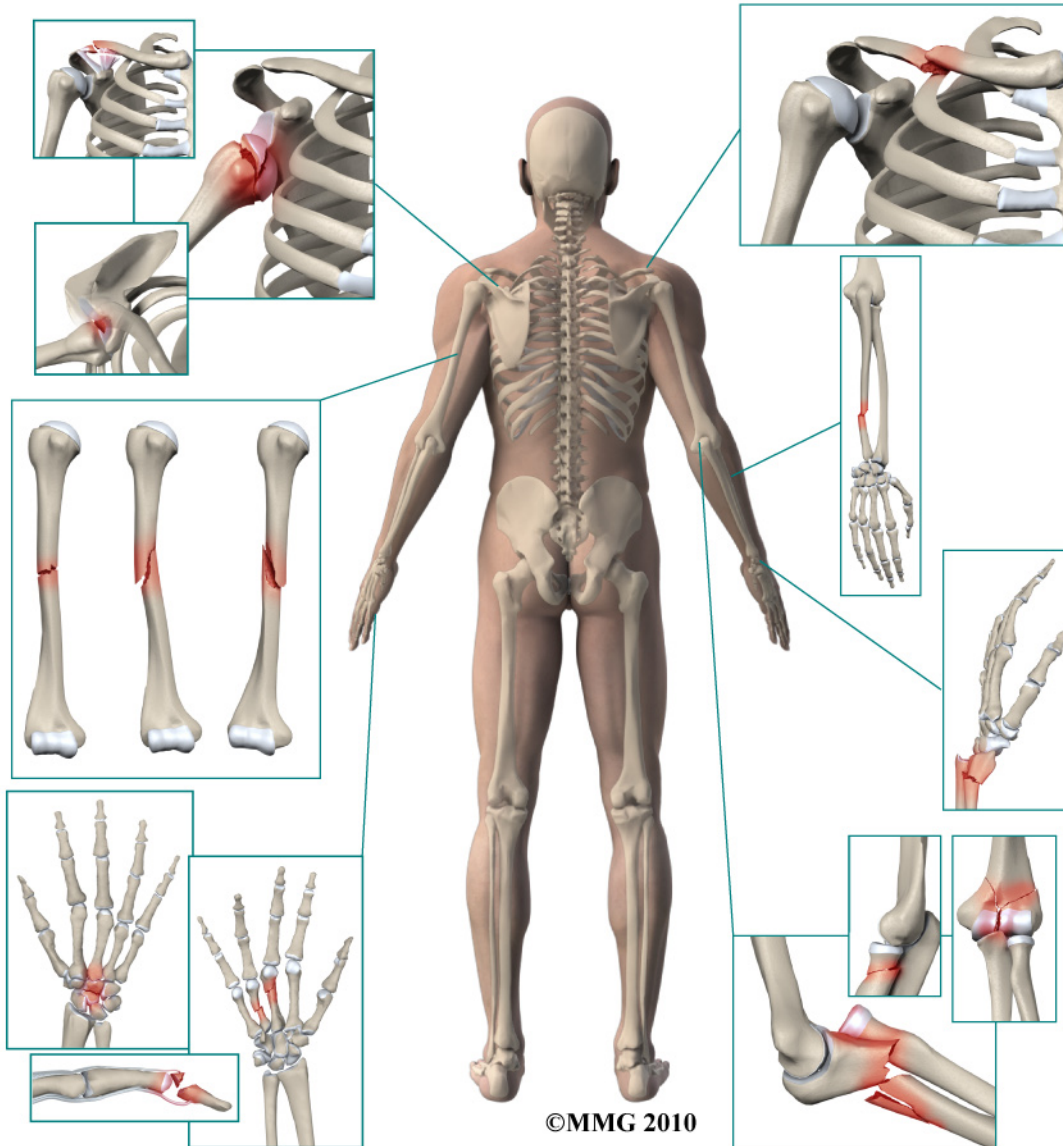


# A Patient's Guide to Adult Distal Radius (Wrist) Fractures



**Centre for Orthopaedics**  
**Suite 10-33/34/35 Mount Elizabeth Novena Specialist**  
**Centre**  
**38 Irrawaddy Road**  
**Singapore, 329563**



## Centre for Orthopaedics

Please take the time to explore our web office. Discover all we have to offer. We hope you will find the time spent on our website rewarding and informative. Here at the Centre for Orthopaedics, we are dedicated to providing ways for those we serve to access the information needed to make informed decisions about healthcare in orthopaedic and sports medicine.

We encourage you to explore our site and learn more about our practice, staff, facilities and treatment options. Check out the Patient Resources section of our site. You will find educational materials to help you understand orthopaedic problems and what options for treatment are available in our clinic.

The Staff of the Centre for Orthopaedics.

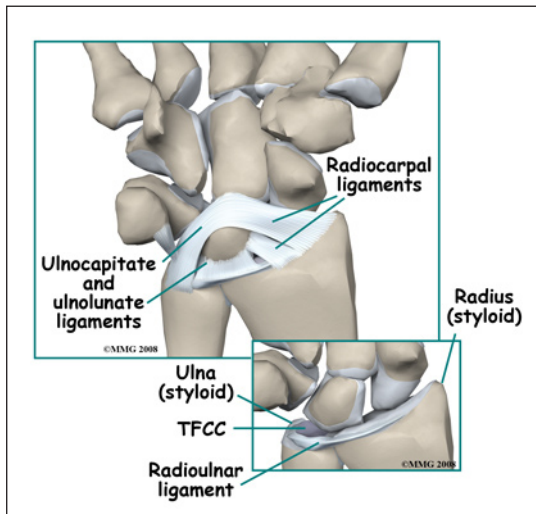
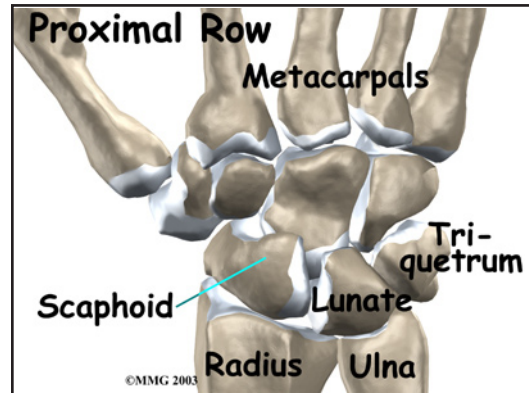


Centre for Orthopaedics  
Suite 10-33/34/35 Mount Elizabeth Novena Specialist Centre  
38 Irrawaddy Road  
Singapore, 329563  
Phone: (65) 6684 5828 Fax: (65) 6684 5829  
sharon@cfo.com.sg  
<http://www.cfo.com.sg>

# Adult Distal Radius (Wrist) Fractures

## Anatomy

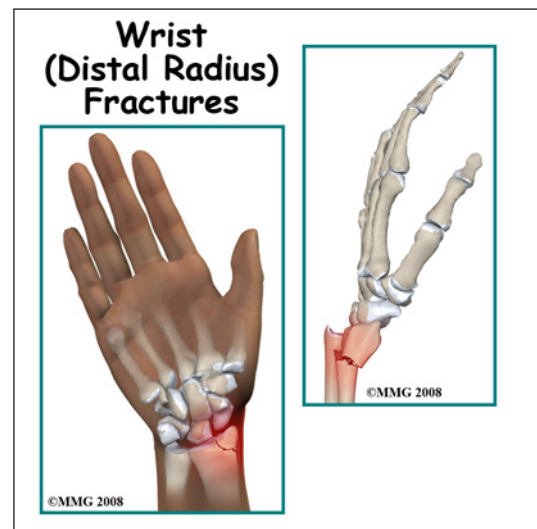
The *distal radius* is part of the *radius*, one of the two bones in the forearm. The distal radius is the name given to the end of the bone that helps form the wrist joint. The distal radius *articulates* (moves against) with three of the eight *carpal bones* of the wrist. This *proximal row* of carpal bones includes the *scaphoid* (navicular), the *lunate*, and the *triquetrum*. Like most joints, the surface of the distal radius that makes up the wrist joint is covered with a smooth, slippery surface called *articular cartilage*.



The edge of the distal radius also articulates with the *ulna* (the other bone that makes up the forearm) and forms a joint called the *Distal RadioUlnar Joint* (DRUJ). A special ligament called the *Triangular FibroCartilage* (TFC) connects the distal radius to the distal ulna. The *TFCC* (*Triangular FibroCartilage Complex*) allows the distal radius to rotate around the ulna in order to place the hand either palm up (called *supination*) or palm down (called *pronation*) - and all points in between.

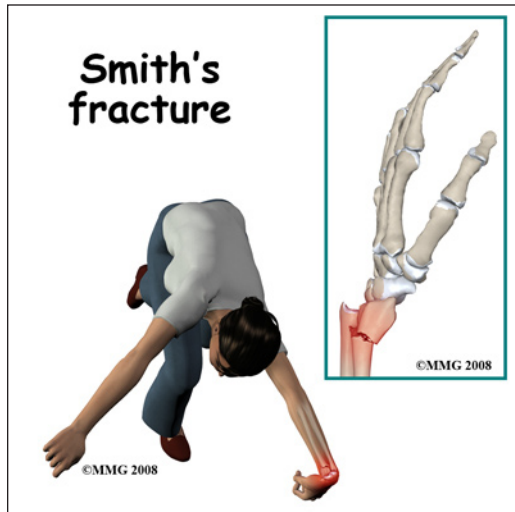
## Signs and Symptoms

A distal radius fracture is usually caused by a fall on the outstretched hand. There is immediate pain and swelling in the wrist. You may also see that the wrist is deformed; this is sometimes referred to as the *silver fork deformity* because the arm looks like the bend in the fork when viewed from the side. Motion is painful; you will probably not be able to grip with the fingers due to pain. You may experience tingling or numbness in the fingers due to compression or stretching of the nerves that cross the wrist.



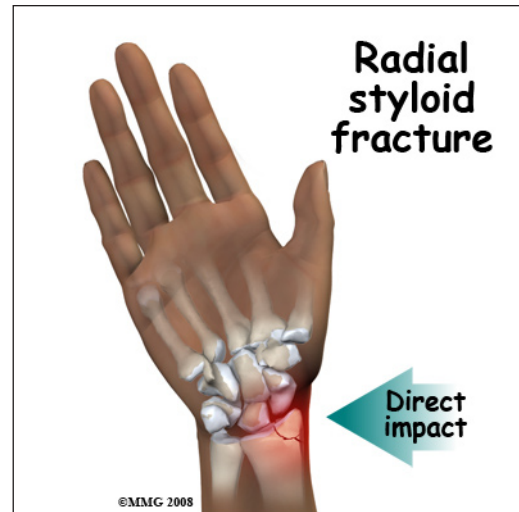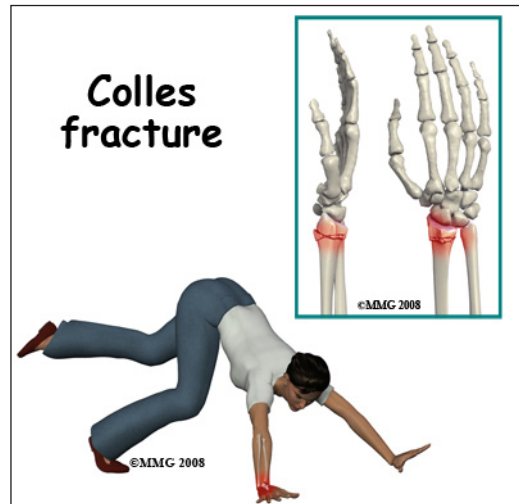
## Evaluation

The primary goal of the clinical evaluation of a distal radius fracture is to determine the pattern of the fracture. Based on the fracture pattern, your surgeon



will need to decide if 1) the fracture is in stable alignment and can be simply protected in a cast or brace until it heals; 2) the fracture pattern can be reduced (or manipulated) to a stable alignment without surgery and held with a cast or brace until it heals;

or 3) surgery will be necessary to align the fracture fragments and fix the fragments with some combination of metal pins, metal plates, and metal screws. The fracture is evaluated by taking several x-rays of the wrist and elbow. In some special cases where surgery is anticipated, a CAT Scan may be necessary to identify all the fragments and plan the surgical procedure. Your surgeon will also want to make sure that there has been no damage to the *median* and *ulnar* nerves. This can usually be accomplished with a careful physical examination.



## Treatment

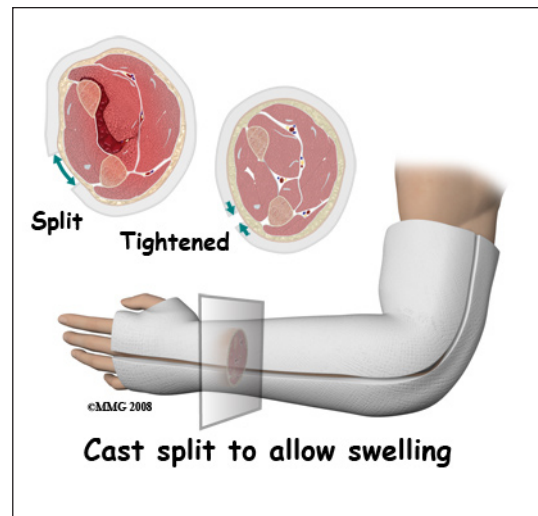
Many distal radius fractures are simple cracks that do not displace and do not require surgery. The more fragments, and the more displaced the fragments are, the more likely some type of surgery will be required. The wrist joint is a complex joint that relies on multiple bones and ligaments to function correctly. When a distal radius fracture is combined with a ligament injury, both structures must be considered in the decision whether to recommend surgery or not. The surface of the distal radius is covered with articular cartilage. This glistening, smooth material allows a joint to *articulate* (or move) smoothly and painlessly. When a fracture causes damage or unevenness to the articular surface of the joint, wear and tear can occur over time. The distal radius joint surface needs to be repaired as close to normal as possible to reduce the risk of developing wear and tear arthritis of the elbow joint.

## Nonsurgical

Distal radius fractures can be treated without surgery if the fragments are minimally displaced, meaning that the fragments remain in close connection and do not cause unevenness of the distal radius joint surface. If your surgeon decides that the fracture can be treated without surgery, a padded splint is usually applied for the first one or two weeks. Unlike a cast, a soft, bulky splint allows for changes in the amount of swelling that will occur over the first few days or weeks. After the swelling has subsided, a short arm cast, long arm cast or fracture brace is usually recommended.

If your surgeon decides that the fragments can be manipulated (or moved) into alignment without surgery, then a *closed reduction* will be performed. To perform a closed reduction, a local anesthetic block is used to numb the arm around the fracture. Once the arm is numb, the surgeon will use a combination of pulling and pushing to align the fracture fragments into an acceptable position. A splint or cast is then applied immediately to hold the fracture in position.

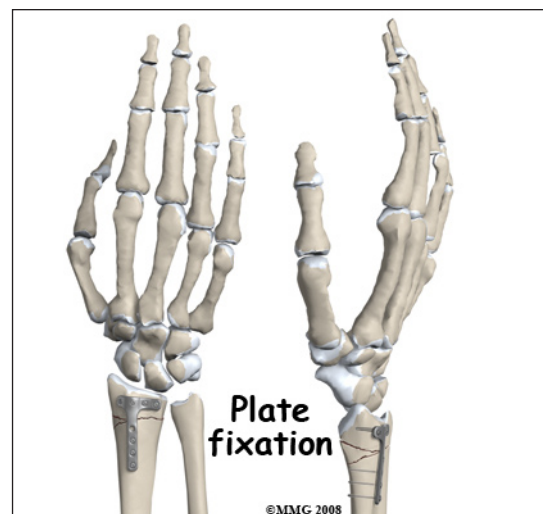
The cast or fracture brace will remain in place until the fracture shows signs of healing. This usually occurs at six or eight weeks. X-rays are normally taken after one or two weeks to make sure that the fracture fragments are not separating and again several times throughout the treatment period to assess whether the fracture is healing. Once your surgeon thinks that the fracture has healed, the cast or fracture brace is discontinued and you will work with a physical therapist to regain the motion and strength in the arm and hand.



## Surgery

Distal radius fractures commonly require surgery. If your surgeon makes the assessment that the fracture will NOT give you good wrist function without surgery, surgical treatment will be recommended. If the fracture cannot be held in acceptable position with a cast or fracture brace and the fragments begin to separate, surgery may be suggested after several days or weeks of attempting nonsurgical treatment. Surgical treatment of distal radius fractures can be performed in three ways: metal pins placed through the skin and into the fracture fragments to hold them in place, a metal plate and screws along the side of the bone, or an external fixator with metal pins through the skin.

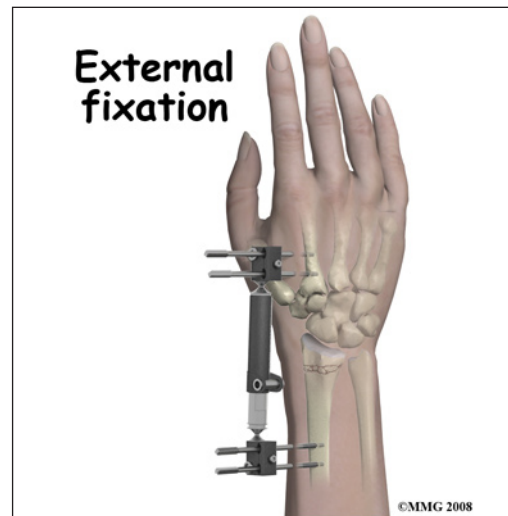
Surgical treatments that range from relatively simple to more complex may be considered depending on



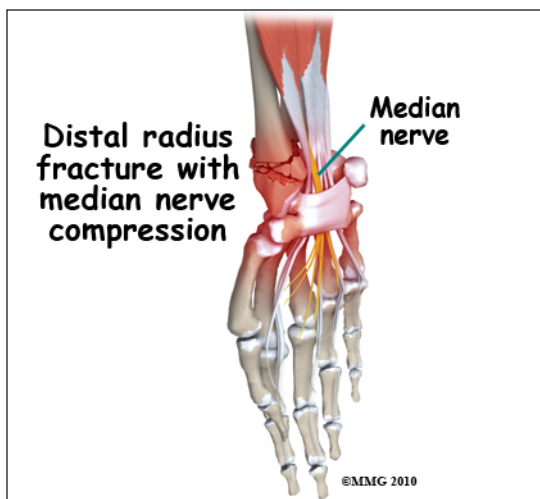
the fracture pattern. Simple fracture patterns may be treated by placing metal pins through the skin and into the bone fragments to hold the fragments in position as they heal. These pins are inserted while you are in the operating room with the aid of a special X-ray machine called a *fluoroscope*. The fluoroscope allows the surgeon to see an X-ray image of the bones on a television monitor and guide the placement of the pins by viewing this image. This type of surgery may be done as an outpatient.

Many distal radius fractures require *Open Reduction and Internal Fixation (ORIF)* using a metal plate and screws. This type of treatment allows the fracture fragments to be restored as close to their normal position as possible and held there with the plate and screws until healing occurs. This type of treatment may be necessary to restore the joint surface as close as possible. Depending on the fracture pattern, ORIF may require an incision on the back of the wrist (*dorsal*) or the front of the wrist (*volar*), sometimes both.

*External fixation* is an option for some distal radius fractures. The external fixation device allows the surgeon to place metal pins through the skin and into the bone fragments away from the fracture site. These metal pins are then connected to a metal frame *outside the skin*. The external fixation device relies on the ligaments connected to the fracture fragments to hold the fragments in alignment as they heal. Once the fracture has healed, the external fixation device is removed. This usually can be done in the office and does not require another operation. The external fixation device can be combined with metal pins or metal screws if necessary to help hold the fragments in place. The combination of the external fixation device and a few well-placed pins or screws is sometimes used to limit the need for larger incisions and reduces the amount of tissue damage around the wrist.



## Complications



Nearly all fractures can result in damage to nerves and blood vessels; this can occur after a distal radius fracture. Perhaps the most common nerve problem that is encountered due to a distal radius fracture is injury or compression of the *median nerve*. This nerve runs into the hand through the carpal tunnel, lying very close to the undersurface of the distal radius. When the distal radius is fractured, the median nerve can either be stretched as the fracture displaces (or separates) or the swelling caused by the fracture can cause pressure on the nerve. Injury caused by stretching of the nerve will usually resolve on its own, but if there is ongoing pressure on the nerve caused by swelling,

this may need to be treated to reduce the risk of permanent nerve damage. If there are signs and symptoms that the nerve is not functioning correctly, your surgeon may recommend an operation to release the pressure on the nerve.

*Chronic Regional Pain Syndrome (CRPS)* is another uncommon, but serious, potential complication of distal radius fractures. The cause of this problem is unknown; CRPS can occur anywhere in the body but is more common in the extremities - the arm and leg. In a few patients following a fracture of the distal radius, the arm and hand become immediately swollen and intensely painful. The nervous system of the extremity seems to become deranged. Treatment consists of medications to control the nerve pain, injections to block the sympathetic nerves to the extremity in an attempt to stop the process and physical therapy to regain function as soon as possible. CRPS can be very frustrating and become a chronic condition; luckily, the complication is rare.

The fracture fragments may fail to heal; this is referred to as a *nonunion*. The fracture fragments may also heal in an unacceptable alignment; this is called *malunion*. If either of these complications occur, the result may be pain, loss of strength and a decreased range of motion of the wrist. A second operation may be needed to treat the complication.

Because the distal radius makes up part of the wrist joint surface, a fracture of the distal radius may damage the articular cartilage surface. This may lead to *osteoarthritis* (wear-and-tear arthritis) of the wrist joint months or years after the fracture has healed. You will always have some risk of developing osteoarthritis after a distal radius fracture because of the damage to the articular surface caused by the fracture. Osteoarthritis of the wrist may result in pain and stiffness of the wrist joint and may require additional treatment or surgery if the symptoms are severe.

## **Rehabilitation**

The prognosis for simple distal radius fractures is generally excellent. The more comminuted distal radius fractures and those that involve other injuries to the ligaments of the wrist are more likely to result in longer healing time and may require more extensive physical therapy to regain wrist function. If treatment requires prolonged immobilization of the wrist, your shoulder may become somewhat stiff because you will not be using the joint normally. Physical therapy is usually recommended to regain both strength and range of motion in the shoulder and entire arm.

Rehabilitation will begin once your surgeon feels that the fracture is stable enough to begin regaining the range of motion in your shoulder, elbow and wrist. If surgery has been required, the rehabilitation program will be modified to protect the fixation of the fracture fragments. Your surgeon will communicate with your physical therapist to make sure that your rehabilitation program does not risk causing the fixation to fail. If the surgeon feels that the fixation is very solid, you may be able progress your program quickly; if the fixation is not so solid, the speed at which you progress may need to be slowed until more healing occur.

*NOTE: For further information about fractures visit [www.eOrthopod.com](http://www.eOrthopod.com)*

## **Notes**